



ISSN: 0975-833X

Available online at <http://www.journalcra.com>

International Journal of Current Research  
Vol. 15, Issue, 06, pp.24871-24874, June, 2023  
DOI: <https://doi.org/10.24941/ijcr.45459.06.2023>

INTERNATIONAL JOURNAL  
OF CURRENT RESEARCH

## RESEARCH ARTICLE

# AESTHETIC ENHANCEMENT OF DISCOLOURED NON-VITAL TEETH – A CONSERVATIVE APPROACH

Dr. Pradnya V. Bansode<sup>1</sup>, Dr. Seema D. Pathak<sup>2</sup>, Dr. Wavdhane<sup>3</sup>, M. B. and Dr. Nisha Dalal<sup>\*4</sup>

<sup>1</sup>Head of Department, Professor, Department of Conservative Dentistry and Endodontics, GDC & Hospital, Aurangabad/ MUHS, India; <sup>2</sup>Professor, Department of Conservative Dentistry and Endodontics, GDC & Hospital, Aurangabad/ MUHS; <sup>3</sup>Associate Professor, Department of Conservative Dentistry and Endodontics, GDC & Hospital, Aurangabad/ MUHS, India; <sup>4</sup>MDS student, Department of Conservative Dentistry and Endodontics, GDC & Hospital, Aurangabad/ MUHS, India

### ARTICLE INFO

#### Article History:

Received 18<sup>th</sup> March, 2023  
Received in revised form  
11<sup>th</sup> April, 2023  
Accepted 26<sup>th</sup> May, 2023  
Published online 23<sup>rd</sup> June, 2023

#### Keywords:

Aesthetics, Non-vital bleaching,  
Conservative technique, Walking bleach  
technique.

\*Corresponding Author: Dr. Nisha Dalal

Copyright©2023, Pradnya V. Bansode et al. This is an open access article distributed under the Creative Commons Attribution License, which permits unrestricted use, distribution, and reproduction in any medium, provided the original work is properly cited.

Citation: Dr. Pradnya V. Bansode, Dr. Seema D. Pathak, Dr. Wavdhane, M. B. and Dr. Nisha Dalal. 2023. "Aesthetic enhancement of discoloured non-vital teeth –A conservative approach". *International Journal of Current Research*, 15, (06), 24871-24874

### ABSTRACT

**Objective:** Nasal continuous anterior teeth are an integral part of facial aesthetics as they are involved in complex social and cultural interactions and have a high social impact. Discoloration of non-vital teeth is intrinsic in nature and can be of various aetiologies. A conservative treatment modality for managing such cases is through non-vital bleaching technique. Many methods to bleach non-vital teeth have been suggested. The most recommended procedure is the walking bleach technique. This technique is known to be simple, safer, and more agreeable to both the patients as well as dentists. The case reports in the present article aim to demonstrate the successful aesthetic rehabilitation of discoloured non-vital maxillary anterior teeth using walking bleach technique.

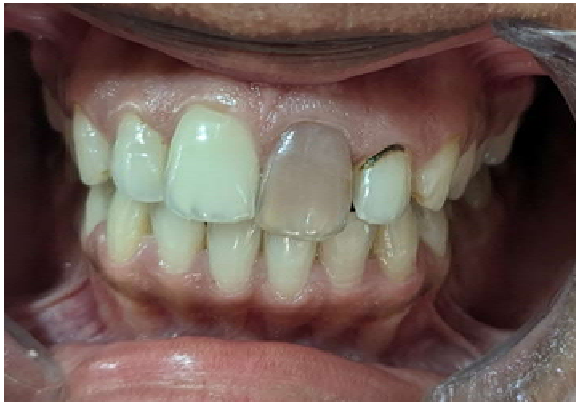## INTRODUCTION

Aesthetics is a field of growing importance, especially because having an aesthetic smile has a psychosocial impact that influences the individual's self-perception. (1) Discoloration of teeth, mostly in the anterior region, can lead to significant impairment in the cosmetic appearance of an individual. Discoloration of a non-vital tooth is an externalization of the diseased state of the pulp-dentin complex which is visible through the enamel due to its inherent translucent nature. The visual impact of discoloured teeth is considerably greater when a chromatic change occurs in a single tooth, as the colour discrepancy with the remaining teeth becomes more evident. (1) Non-vital tooth discoloration may have many causes, namely dental trauma, presence of necrotic debris in the pulp horns and dentinal tubules (1), calcific metamorphosis, poor irrigation, or sealing materials located in the pulp chamber or chamber walls. (1) Necrosis of the tooth pulp results in the release of disintegration by-products and these may infiltrate tubules, thereby discolouring the surrounding dentin. Acute trauma to a tooth can cause intra-pulpal haemorrhage, thereby giving it a reddish tinge which can later change to grey-brown as time passes due to pulpal necrosis. The haemolysis of the red blood cells causes the

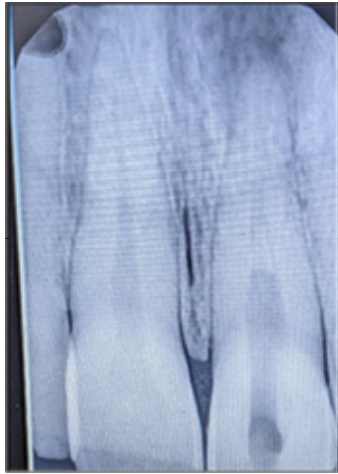
The released haem, in turn, combines with the necrosing pulpal tissue to form iron sulphide, which is black in colour. Non-vital teeth that are extensively discoloured are highly receptive for bleaching techniques. (2) Internal tooth bleaching is a minimally invasive, conservative, relatively simple, effective, and low-cost method in the treatment of discoloured endodontically treated teeth. (1) Various methods to bleach non-vital discoloured teeth have been proposed, the most common being the walking bleach technique. It is the most recommended method as it is simple, safe, with lower risks and suitable for patients and dentists. The following case report aims to illustrate the successful aesthetic enhancement of discoloured non-vital anterior teeth using the walking bleach technique.

## CASE REPORT

A 25-year-old female patient reported to the Department of Conservative Dentistry and Endodontics, Government Dental College and Hospital Aurangabad, Maharashtra complaining of pain, discolouration with her left maxillary right central incisor, i.e. 21.

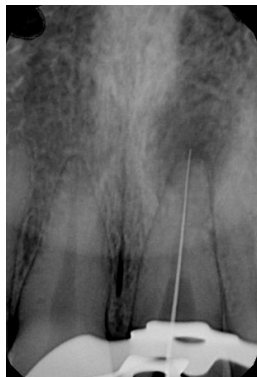

**Pre-operative photograph**



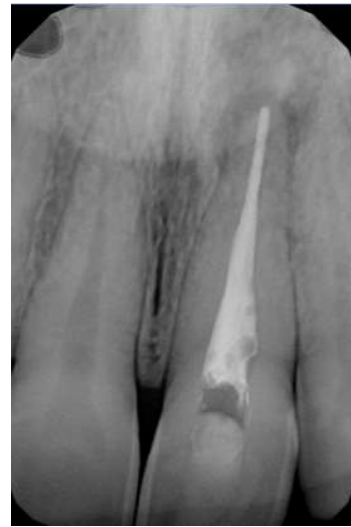**Pre-operative radiograph**

The patient gave a history of trauma 7 years ago in the same region. On clinical examination, Ellis class IV fracture with yellowish-brown discoloration of the crown was observed with 21. Intraoral periapical radiograph revealed periapical rarefaction with 21. The tooth also gave a negative response to the electric pulp sensitivity test as compared to the adjacent and contralateral teeth.



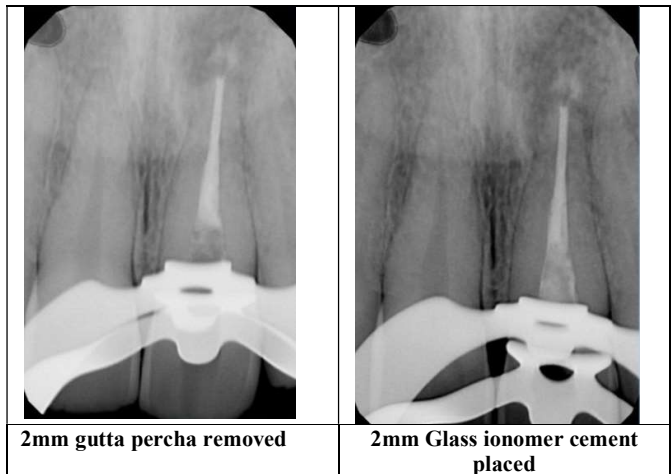
**Working length determination**

Based on these findings, a provisional diagnosis of chronic periapical lesion with 21 was established. After discussing the treatment options with the patient, a conservative approach of root canal treatment followed by non-vital bleaching and composite resin restoration of 21 was opted. Access opening and complete biomechanical preparation of 21 was done under rubber dam isolation. Calcium hydroxide was placed as an intracanal medicament and the patient was recalled after

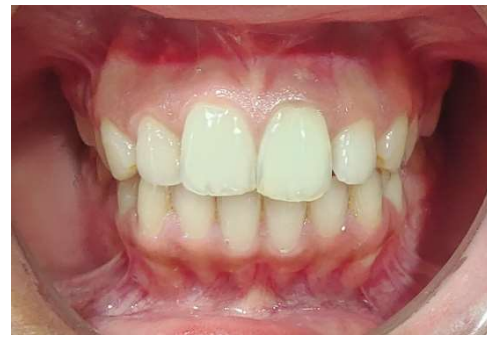


**Post-obturation radiograph**

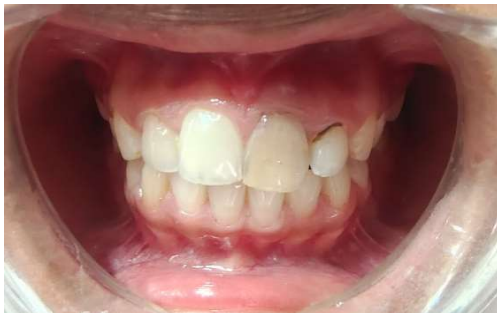As the patient was asymptomatic, obturation of 21 with lateral condensation of gutta-percha was done, the access cavity was sealed using Cavit G (3M ESPE) temporary restorative material and the patient was recalled after a week for the bleaching procedure. After isolation of the tooth using rubber dam, the temporary restoration was removed, and the endodontic access cavity was modified to ensure that no filling remnants were present in the pulp chamber and pulp horns. The gutta-percha filling was removed from the access cavity 2mm apical to the cemento-enamel junction using gates-glidden drills. A 2 mm plug of glass ionomer restorative cement was then placed over the gutta-percha in the cervical region to seal the cervical dentinal tubules and prevent percolation of bleaching agent to the surrounding periodontal tissues.



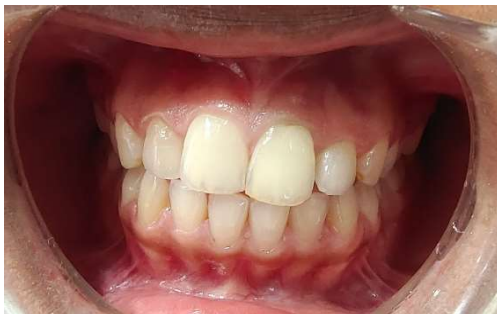In a dappen dish sodium perborate powder was mixed with distilled water to obtain a thick paste which was then placed inside the access cavity of 21. Cotton pellets were used to blot off the excess liquid from the paste. A temporary restoration was packed on top of the paste using glass ionomer restorative cement to ensure a good seal and the rubber dam isolation was removed. The patient was recalled after every 7 days for assessment of the bleaching results. Weekly replacement of the bleaching agent with a fresh paste of sodium perborate was also done by repeating the same procedure. After 3 weeks, the anticipated bleaching results were achieved with an improved cosmetic appearance. After the completion of bleaching treatment, the pulp chamber was cleaned, dried. The cavity was closed with Cavit G (3M ESPE) temporary restorative material and the patient was called after 2 weeks for permanent restoration and build-up of the fractured tooth structure with composite resin.



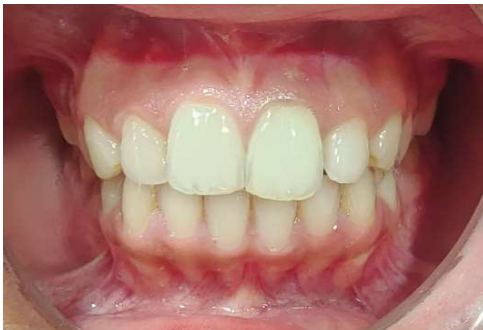Post-operative photograph



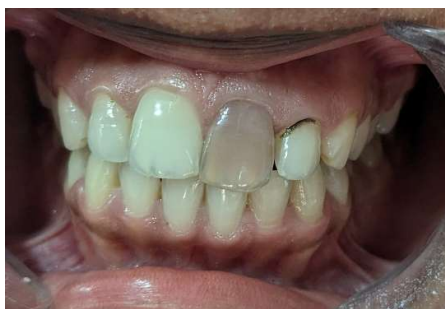Bleaching result after 1st week



Bleaching result after 2nd week



Bleaching result after 3rd week



Pre-operative photograph

## DISCUSSION

Discoloured anterior teeth should be considered as a significant aesthetic impairment which can compromise patient's physical, psychological and social well-being. Non-vital bleaching is the minimally invasive procedure for esthetic rehabilitation of discoloured non-vital teeth. (2) First described by Spasser in 1961, the walking bleach technique can be described as enclosing a mixture of sodium perborate and water within the pulp chamber of the discoloured non-vital tooth. (3) Sodium perborate is stable when in the form of a dry powder but, in the presence of acid, warm air or water, it decomposes to form metaborate, hydrogen peroxide and nascent oxygen. (4) The complex carbonic chains of the pigment are transformed into CO<sub>2</sub> and H<sub>2</sub>O, being gradually released together with the nascent oxygen (5), resulting in smaller molecules with free hydroxyls (which reflect the blue light along with the green and red spectra), thus giving the whitening effect.

There are risks associated with non-vital teeth bleaching, the most serious of which is external cervical root resorption. Presumably, the diffusion of hydrogen peroxide through the dentinal tubules and micro-perforations of the intra-orifice barrier cement in the cervical periodontal ligaments is responsible for the destruction of the hard tissues at the level of the cemento-enamel junction. (1) It has been established that 30% hydrogen peroxide alone or in combination with sodium perborate are more cytotoxic for periodontal cells than perborate-water mixture. (2) Heat application causes widening of dentinal tubules, facilitating easier diffusion of hydrogen peroxide to the periodontium. (6) Hence, the use of hydrogen peroxide was substituted with warm distilled water and heat activation of the mixture was avoided. The prevention of the percolation of bleaching agents into the surrounding peri-radicular tissues is impertinent. This is achieved by ensuring that a proper cervical barrier is placed at the level of the cemento-enamel junction and a good seal is achieved. In this case glass ionomer cement was used as the barrier material. The shape of the barrier was kept as 'bobsled tunnel' facially. (7) The cervical barrier of such shape blocks all the dentinal tubules which run from pulp chamber to external tooth surface apical to the level of epithelial attachment, thereby securing the bleaching agent within the pulp chamber cavity, which in turn prevents the incidence of external root resorption occurring as a side effect of the treatment procedure. (7)

## CONCLUSION

Internal bleaching is a conservative, simple, effective, and low-cost treatment plan, with good esthetic results, for the management of non-vital tooth discolorations. Walking bleach technique is the most common method used for this purpose. In order to prevent seepage of hydrogen peroxide through dentine, it is necessary to place a dense root filling and an additional cervical seal prior to starting the walking bleach procedure. (8) Proper treatment protocol must be followed, and adequate precautions should be employed to avoid risks associated with this procedure.

## REFERENCES

1. Coelho, Ana & Garrido, Lara & Mota, & Marto, Carlos & Amaro, Inês & Carrilho, Eunice & Paula, (2020). Non-Vital Tooth Bleaching Techniques: A Systematic Review. *Coatings*. 10. 61. 10.3390/coatings10010061.
2. Pandey SH, Patni PM, Jain P, Chaturvedi A. Management of intrinsic discoloration using walking bleach technique in maxillary central incisors. *Chujul Med*. 2018;91(2):229-233. doi: 10.15386/cjmed-852. Epub 2018 Apr 25. PMID: 29785163; PMCID: PMC5958990
3. Sulieman, M. (2005). An Overview of Bleaching Techniques: 2. Night Guard Vital Bleaching and Non-Vital Bleaching. *Dental Update*, 32(1), 39–46. doi:10.12968/denu.2005.32.1.39
4. Rokaya ME, Beshr K, Hashem Mahram A, Samir Pedir S, Baroudi K. Evaluation of Extraradicular Diffusion of Hydrogen Peroxide during Intracoronaral Bleaching Using Different Bleaching Agents. *Int J Dent*. 2015; 2015:493795. doi: 10.1155/2015/493795. Epub 2015 Jul 14. PMID: 26257782; PMCID: PMC4516840.
5. Junior MT, Rodrigues CA, Bernardes VL, Araujo TSB, Nicoli GA, *et al.* (2018) Dental Bleaching and New Possibilities - Literature Review. *Health Sci J* Vol. 12. No.6:600. DOI: 10.21767/1791-809X.1000600
6. Rotstein I, Torek Y, Lewinstein I. Effect of bleaching time and temperature on the radicular penetration of hydrogen peroxide. *Endod Dent Traumatol*. 1991; 7(5):196–198.
7. Sundesha M, Tomar M, Bhalodi D, Gupta T, Choudhary A. Management of non-vital maxillary central incisor with intrinsic discoloration using walking bleach technique. *IP Indian J Conserv Endod* 2021;6(3):181-184.
8. Attin, T., Paqué, F., Ajam, F. and Lennon, Á.M. (2003), Review of the current status of tooth whitening with the walking bleach technique. *International Endodontic Journal*, 36: 313-329

\*\*\*\*\*