



ISSN: 0975-833X

Available online at <http://www.journalcra.com>

*International Journal of Current Research*  
Vol. 15, Issue, 08, pp.25763-25765, August, 2023  
DOI: <https://doi.org/10.24941/ijcr.45806.08.2023>

**INTERNATIONAL JOURNAL  
OF CURRENT RESEARCH**

## RESEARCH ARTICLE

### SOLITARY PALATAL RECURRENCE IN DIFFUSE LARGE B-CELL LYMPHOMA: A RARE CASE

<sup>1</sup>Avinash, <sup>2</sup>Rupender K Ranga, <sup>3</sup>SPS Yadav and <sup>4</sup>Satyavir Yadav

<sup>1</sup>Medical Officer, Bharat ENT & Endoscopy Hospital, Rohtak Gate, Bhiwani, Haryana (India) 127021

<sup>2</sup>Director, Bharat ENT & Endoscopy Hospital, Rohtak Gate, Bhiwani, Haryana (India) 127021

<sup>3</sup>Ex Sr. Prof & HOD - ENT Dept. PGIMS-Rohtak, Haryana (India) 124001

<sup>4</sup>Yadav Pathology Lab, Bhiwani, Haryana (India) 127021

#### ARTICLE INFO

##### Article History:

Received 29<sup>th</sup> May, 2023  
Received in revised form  
18<sup>th</sup> June, 2023  
Accepted 15<sup>th</sup> July, 2023  
Published online 30<sup>th</sup> August, 2023

##### Key words:

DLBCL, Palate, R-CHOP,  
Immunohistochemistry

##### \*Corresponding Author:

Avinash

Copyright©2023, Avinash et al. This is an open access article distributed under the Creative Commons Attribution License, which permits unrestricted use, distribution, and reproduction in any medium, provided the original work is properly cited.

Citation: Avinash, Rupender K Ranga, SPS Yadav and Satyavir Yadav, 2023. "Solitary palatal recurrence in diffuse large B-cell lymphoma: A Rare Case". *International Journal of Current Research*, 15, (08), 25763-25765.

#### ABSTRACT

Palatal recurrence of diffuse large B-cell lymphoma after completion of chemotherapy is rare clinical entity Lymphoma has a propensity for recurrence in any part of the body. PET scan is the modality of first choice to rule out recurrence of NHL after completion of chemotherapy. Biopsy is the gold standard for diagnosis and staging of Non Hodgkin Lymphoma (NHL). Histopathology and immune his to chemistry decides the treatment. In elderly patients, treatment with R-mini CHOP regime has excellent role without any complications.

## INTRODUCTION

Lymphoma is not an uncommon malignant tumor in head and neck region, reported incidence is 12%- 15%. It is a haematolymphoidneoplasm that affects nodal and extra nodal sites. Extra nodal involvement sites in head & neck are nasopharynx, lacrimal sac, temporal bone with facial palsy, intra oral manifestations like ulceration, pain, swelling and tooth mobility has been reported in literature<sup>1</sup>. Multiple factors are responsible for etiology of lymphoma. It is strongly associated with Epstein barr virus (EBV). Non-Hodgkin Lymphoma (NHL) is disorder of lymphocytes, can be indolent or aggressive, presents in old age male having weakened immune system that leads on to adult NHL. Palatal involvement in lymphoma is unusual clinical entity. Solitary palatal involvement in NHL is unreported, one such case is reported here.

## CASE REPORT

A 74 years old male visited Otorhinolaryngological services for routine examination. Examination revealed a noval, smooth swelling of about 3x2 cm in dimension on right side of soft palate. He was inquired about his past medical history revealed that he underwent treatment of NHL 10 years back with R-CHOP regime.

However, there was no lesion in the palate at that time. After completion of treatment, the patient was leading symptom free and healthy life. There was no history of smoking. However, occasional social drinking history was present. He was non diabetic & not hypertensive. Ear, nose and neck examination was unremarkable. F18-FDG PET (Fluorine 18 Fluoro Deoxy Glucose Positron Emission Tomography) scan was done keeping in view the past history of NHL which revealed active metabolic lesion with radioactive tracer uptake at palatal region. Punch biopsy was carried out from palatal swelling. Histopathological examination (HPE) revealed the diffuse sheets of uniform small to medium sized lymphoid cells with irregular nuclear membrane, clumped chromatin, variable pin-point nucleoli and scanty cytoplasm. Immunohistochemically (IHC) tumor cells were diffusely and strongly positive for CD20 with kappa light chain reaction (kappa > lambda) and significant proliferative index (Ki-67) of 45-50% in the hot-spot area. Subset of tumor cells also expressed CD23, BCL-6 and MUM-1, while it was negative for CD3, CD5, CD10, Cyclin D1 and CD138. Histopathologically and IHC diagnosis was diffuse large B-cell NHL (DLBCL). Treatment started under the guidance of medical oncologist. The patient was treated with R-CVP regime (R-Rituximab 375mg/m<sup>2</sup>, C-Cyclophosphamide 750mg/m<sup>2</sup>, V-Vincristine 1.4mg/m<sup>2</sup>, P-Prednisolone 40mg/m<sup>2</sup>) for 2 cycles. However, after 2 cycles adverse effect of Vincristine appeared in the form of peripheral neuropathy, therefore, the regime was

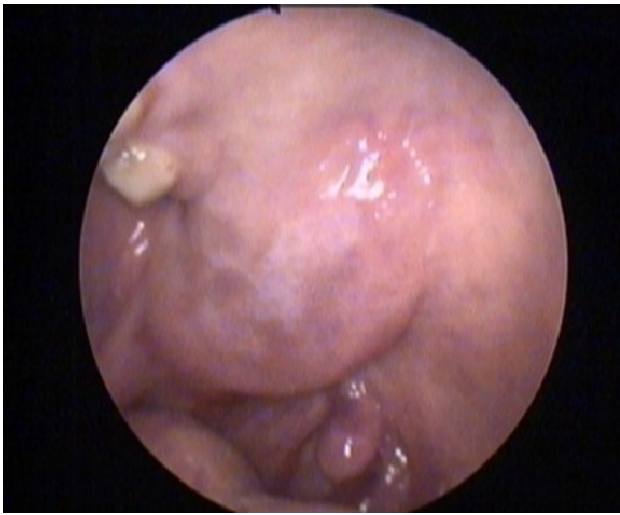

Fig. 1. Showing oval shape swelling on soft palate

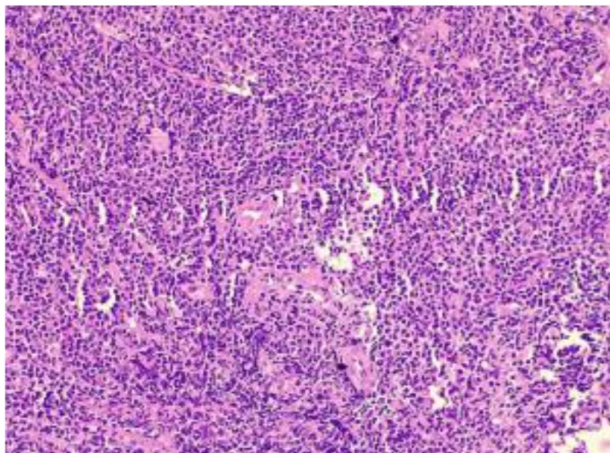


Fig. 2 H & E stain showing small to medium B lymphocytes with irregular nuclear membrane and scanty cytoplasm

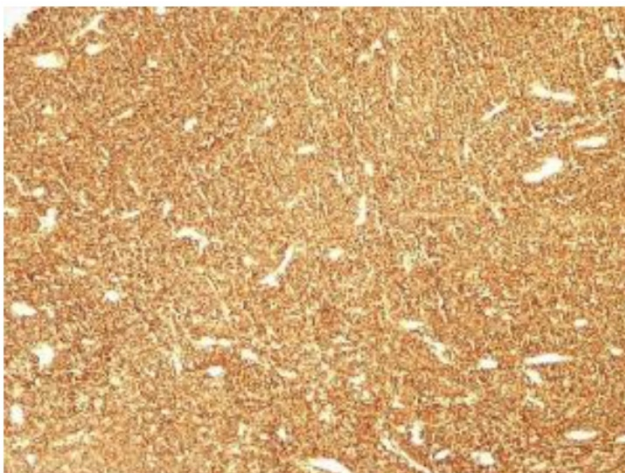

Fig. 3 IHC immunoreactive CD-20 in lesional cells

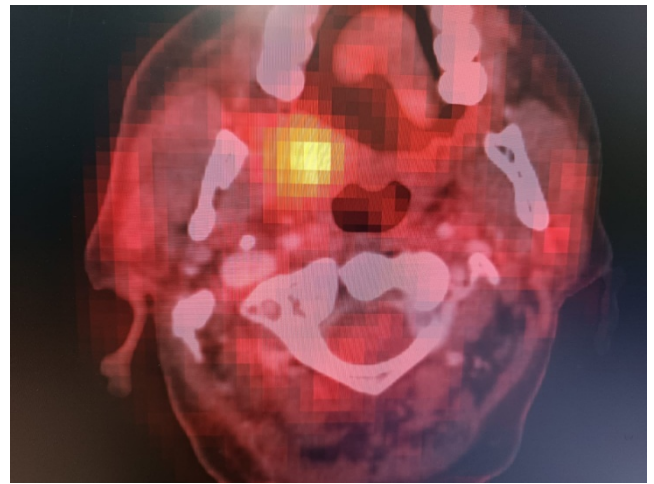


Fig. 4. F18 FDG PET scan showing active metabolic lesion in palate

## DISCUSSION

Lymphomas are heterogenous group of malignant tumors of haematopoietic system and are characterized by aberrant proliferation of mature lymphoid cells or their precursors. It is divided into 2 major groups- Hodgkin Lymphoma (HL) and Non-Hodgkin Lymphoma<sup>2</sup>. Over 20 different subtypes of NHL have been classified according to specific subtypes of lymphoid cells involved. Several classifications of lymphoma have been described in literature by various workers, however, most recent accepted classification by Swerdlow et al (2016)<sup>3</sup>. Histologically lymphoma based on cells of origin: B-cell NHL, T-cell NHL and NK cell NHL (T/NK-NHL) and Hodgkin Lymphoma. Approximately 30% of NHL shows heterogenous extra nodal manifestation such as major salivary glands, PNS, mandible, maxilla and Waldeyer's ring, however, NHL deposits in palate is not reported in literature<sup>1</sup>. Clinicalcourse of NHL presents as painless swelling at nodal and extra nodal sites<sup>3</sup>. Reported case showed accidental finding on palate as a part of routine ENT examination. The DLBCL can be deposited in soft as well as hard palate. Indolent type of NHL represents as painless swelling without any other constitutional symptoms, whereas aggressive type have fever, night sweats, weight loss, fatigue and swollen lymph nodes. Recurrence and deposits are the nature of NHL. Even after completion of treatment recurrence is known<sup>3</sup>.

F18-FDG PET Scan is non-invasive imaging technique to rule out glucose uptake of metabolically active lymphoma cells<sup>4</sup>. Special camera recognizes radioactivity of the cells which showed as hotspot on scan image in the present case. It is an accurate baseline for staging and yields important diagnostic and prognostic information of the lymphomas. It plays important role for initial staging and monitoring morphological changes after treatment. It has greater sensitivity for extra nodal site involvement which show overall metabolic activity of the lymphoma that correlate the level of aggressiveness and with LDH level which assumed as prognostic indicator<sup>5</sup>. Therefore, indolent DLBCL is associated with higher uptake of F18-FDG pre treatment and low after completion of treatment. Punch biopsy is the gold standard for diagnosis and staging of lymphoma. It is rapid, simple, easy to perform, less invasive procedure. Hold the biopsy punch with thumb and index finger of dominant hand and rotate the instrument back and forth under gentle pressure. Standard depth for oral cavity punch biopsy is approximately 4-5mm<sup>6</sup>. Most common complication can be small amount of bleeding which stops spontaneously after local pressure. Haematoxylin and Eosin stain is commonly used for histological diagnosis<sup>6</sup>. Histologically NHL show follicular and diffuse pattern. Follicular lymphoma presents as follicular pattern with uniform nodularity along with little variation in size and shape of follicle. Diffuse pattern have normal architecture effaced by infiltration of small lymphocytes.

changed to Mini R-CHOP (R-Rituximab 375mg/m<sup>2</sup>, C-Cyclophosphamide 400mg/m<sup>2</sup>, H-Hydroxydaunorubicin 25mg/m<sup>2</sup>, P-Prednisolone 40mg/m<sup>2</sup>). Regression of palatal tumor started after 2 cycles and complete regression of tumor occurred in 6 cycles. After completion of chemotherapy F18-FDG PET Scan was done and no FDG avid lesion was observed in soft palate. Blood counts were within normal limit. Whereas Lactate dehydrogenase (LDH) before treatment was 332 U/L and after treatment was 225 U/L. On follow up after treatment the patient was disease free.

There are clear spaces interspersed with reactive histiocytes containing phagocytic debris<sup>7</sup>. Present case was composed of small to medium size of lymphoid cells with slight irregular notched nuclei. The degree of irregularity is usual but not always. IHC provides adequate information for biomarkers like CD-20, which is strongly positive for DLBCL that identifies as prognostic marker for standard treatment and response to chemotherapy<sup>8</sup>.

There are four strategies for treatment of lymphoma i.e., chemotherapy, immunotherapy, targeted therapy and radiation therapy. Chemotherapy of metastatic NHL includes 2 regime- R-CVP and R-CHOP which depends upon tumor stage, grade, type and patients factor like symptoms, age & performance status. Doses of R-CVP regime contain R (Rituximab 375 mg/m<sup>2</sup>), C (Cyclophosphamide 750 mg/m<sup>2</sup>), V (Vincristine 1.4 mg/m<sup>2</sup>), P (Prednisolone 40 mg/m<sup>2</sup>), whereas R-CHOP- R (Rituximab 375 mg/m<sup>2</sup>), C (Cyclophosphamide 750 mg/m<sup>2</sup>), H (Hydroxydaunorubicin 10 mg/m<sup>2</sup>), O (Oncovin 0.4 mg/m<sup>2</sup>), P (Prednisolone 60 mg/m<sup>2</sup>)<sup>9</sup>. Various adverse effects of the regime have been documented in literatures. In our case, peripheral neuropathy caused by Vincristine was observed. However, DLBCL is also known to cause local compression of vessel, airway, involvement of peripheral nerves and destruction of bones. After appearance of peripheral neuropathy we switched on to R- mini CHOP regime, which the patient tolerated very well<sup>10</sup>. It was advocated due to advance stage and immunocompromised status of the patient with the advantage of low dose of CHOP. Chemotherapy decision was based on the patient's medical fitness and risk. If R-CHOP regime appears to be more toxic to elderly patients then switch on to R-mini CHOP regime. This regime is well tolerated by elderly patients as in the present case. Patient received 375 mg/m<sup>2</sup> Rituximab, 400 mg/m<sup>2</sup> Cyclophosphamide, 25 mg/m<sup>2</sup> Doxorubicin, 1 mg Vincristine on 1<sup>st</sup> day of each cycle and 40 mg Prednisone on 1-5 days of the cycle. After completion of the treatment patient was healthy and complete regression of the palatal swelling was observed and LDH level was within normal limit.

## REFERENCES

1. Silva TDB, Ferreira CBT, Leite GB, Pontes JRM, Antunes HS. Oral manifestations of lymphoma: a systemic review. *Ecancermedicallscience* 2016; 10:665-80.
2. Caletrio AB, González JLG, Herrera AM, PérezPB et al. Non Hodgkin's lymphoma in the ENT field. *Acta Otorrinolaringol Esp* 2005; 56(5):215-8.
3. Swerdlow ST, Campo E, Pileri SA, Harris NL et al. The 2016 revision of the World Health Organization classification of lymphoid neoplasm. *Blood.*, 2016; 127(20):2375-90.
4. Ansell SM, Armitage JO. Positron emission tomographic scans in lymphoma: convention & controversy. *Mayo Clin Proc* 2012; 87(6):571-80
5. Purnamasidhi CAW, Suega K, Bakta IM. Association between lactate dehydrogenase levels to the response of Non-Hodgkin's lymphoma in elderly patients who treated with first-line chemotherapy in Sanglah general hospital. *Open Access Maced J Med Sci* 2019; 7(12):1984-86.
6. Lynch DP, Morris LF. The oral mucosal punch biopsy: indications and technique. *J Am Dent Assoc* 1990; 121(1):145-9.
7. Cabanillas F, Velasquez WS, Hagemester FB, Mclaughlin P, Redman JR. Clinical, biological and histological feature of late relapse in diffuse large cell lymphoma. *Blood* 1992; 79(4):1024-28.
8. Chan A, Dogan A. Prognostic and predictive biomarkers in diffuse large B-cell lymphoma. *Surg Pathol Clin* 2019; 12(3):699-707.
9. Walewski J, Kozik EP, Michalski W, Rymkiewicz G, et al. First-line R-CVP versus R-CHOP induction immunochemotherapy for indolent lymphoma with rituximab maintenance. A multicenter, phase-III randomized study by the Polish lymphoma research group-PLRG4. *Br J Haematol* 2020; 188(6):898-906
10. Paschalis A, White A, Corser R, Yeoh C, O' Calaghan A. Diffuse large B cell non-Hodgkin's lymphoma: R-mini-CHOP or physician's choice dose-adjusted chemotherapy in patients over 80 years old. *Haematol Oncol* 2017; 35(52):341.

\*\*\*\*\*