



ISSN: 0975-833X

Available online at <http://www.journalcra.com>

International Journal of Current Research  
Vol. 16, Issue, 01, pp.26865-26866, January, 2024  
DOI: <https://doi.org/10.24941/ijcr.46475.01.2024>

INTERNATIONAL JOURNAL  
OF CURRENT RESEARCH

## RESEARCH ARTICLE

### AN ABNORMALLY DILATED RIGHT ATRIUM IN A PATIENT OF MS WITH MITRAL VALVE REPLACEMENT: A RARE CASE REPORT

Dr. Neera Samar<sup>1</sup>, Dr. Kailash Agarwal<sup>2</sup>, Dr. Mukesh Haritwal<sup>2</sup> and Dr. Sazid

<sup>1</sup>Senior Professor and Unit Head, Department of General Medicine RNT Medical College, Udaipur, Rajasthan.

<sup>2</sup>Junior Resident, Department of General Medicine RNT Medical College, Udaipur, Rajasthan.

#### ARTICLE INFO

##### Article History:

Received 19<sup>th</sup> October, 2023  
Received in revised form  
18<sup>th</sup> November, 2023  
Accepted 15<sup>th</sup> December, 2023  
Published online 19<sup>th</sup> January, 2024

##### Key words:

Forensic, Toxicology, Isopulegol, Drug, Sexual Assault, Synthetic Chemical.

##### \*Corresponding author:

Ajay Kumar Gautam

#### ABSTRACT

**Introduction:** Tricuspid regurgitation encountered in clinical practice are secondary in nature and related to tricuspid annular dilation and leaflet tethering in the setting of RV remodeling caused by pressure or volume overload (or both) and myocardial infarction. Secondary TR is commonly seen in late stage of heart failure due to rheumatic or congenital heart disease with pulmonary artery hypertension, as well as in other type of left sided valvular disease. The current case we are reporting is abnormally RA enlargement in mitral stenosis with mitral valve replacement. **Case Report:** A 50-year-old male presented with a complaint of progressive weight gain and painful swelling of the lower extremities. He had abdominal fullness, diminished appetite and muscle wasting. On detailed clinical examination and relevant investigation, we found that the cause of progressive weight gain was tricuspid regurgitation secondary to PAH which is due to MS (old). **Discussion:** tricuspid regurgitation is common finding in untreated or incompletely treated MS as it led to raised pulmonary artery pressure. Early identification of the disease and its cause is critical, to consider the entire clinical presentation for correct diagnosis which is generally delayed due to the overlapping symptoms of the disease with various specialties. **Conclusion:** Diagnosis and management of tricuspid regurgitation with dilated RA still present considerable challenges and patients warrant referral to higher centers. Its diverse presentation warrants a complete Respiratory, cardiac, and general physical examination.

Copyright©2024, Ajay Kumar Gautam et al. This is an open access article distributed under the Creative Commons Attribution License, which permits unrestricted use, distribution, and reproduction in any medium, provided the original work is properly cited.

**Citation:** Ajay Kumar Gautam, Subhra Kumar Paul, Sanjeev Kumar Gupta, Deepa Verma. 2024. "An abnormally dilated right atrium in a patient of ms with mitral valve replacement: a rare case report". *International Journal of Current Research*, 16, (01), 26865-26866.

## INTRODUCTION

Tricuspid regurgitation is a disease of tricuspid valve that become incompetent that allow to flow backward from the RV into RA, the volume of which is dependent on the driving pressure (RV systolic pressure) and size of regurgitation orifice. The severity and physical signs of TR can vary as a function of PA systolic pressure, the dimension of tricuspid valve annulus, the respiratory cycle dependent changes in RV preload, and RV compliance. significant degree of TR will lead to RA enlargement and elevation of RA and JVP progressively severe TR can lead to ventricularization of the RA waveform. Severe TR is also characterized by RV dilation (RV volume overload) and eventual systolic dysfunction, the progression of which can be accelerated by a concomitant pressure load from PA hypertension or by myocardial fibrosis from previous injury. The ECG feature of RA enlargement include tall peaked P wave in lead II, as well as prominent, upright P wave in lead V1. the absence of ECG evidence of RA hypertrophy in a patient with right sided heart failure who is believed to have MS should suggest tricuspid valve disease. In our clinical case presentation abnormally, dilated RA secondary to severe TR with moderate PAH is a rare finding even patient is treated for MS with mitral valve replacement 10 year back. Possibly suggesting that mild-moderate TR develops before repair of MS with mitral valve repair and further TR progression from mild-moderate to

severe TR occur because of perivalvular leakage of blood from LV to LA due to residual defect in repaired mitral valve over the time of 10 years.

## CASE REPORT

A 50-year-old male farmer from the profession was admitted to Maharana Bhupal Government Hospital, RNT Medical College, Udaipur, Rajasthan with complaints of progressive weight gain and painful swelling of lower extremities over a period of 3 months. The weight gain was progressive even in the presence of appetite loss and swelling of lower limb was initially painless but as swelling increase it become painful. On examination, at the time of admission, patient had tachycardia (PR 130/ min), hypotension (BP- 80/60 mmHg), Respiratory rate 30/min and the patient was conscious, Glasgow coma scale E4V5M6. The patient had no anemia, no cyanosis, no clubbing, no icterus, and no koilonychia. On facial examination, he had puffiness of face with dilated neck veins were present. Patient also had hepatomegaly, ascites, pleural effusion and hepatojugular reflex. Patient had previous history of mitral valve replacement due to severe mitral stenosis 10 years back. patient was clinically diagnosed with a case of suspected TR secondary to PAH. The patient was investigated thoroughly to diagnose TR with dilated right atrium. Routine

investigation showed Hb=10.6/dl, TLC=4460/Cumm, PLT=160 lacs/cumm, urea =43 mg/dl, creatinine =1.1 mg/dl, Total bilirubin =0.48mg/dl, Conjugated bilirubin =0.33 mg/dl, SGOT/SGPT =55/23 u/l, TG= 175 mg/dl, HDL=29 mg/dl, LDL=60 mg/dl. Serum electrolytes Na+=138mEq/L, K=3.8mEq/L, and CL=97mEq/L. Her viral markers (HBV, HCV, HIV) were also negative. Her hormones assays showed T3=0.874 nmol/L (1.3-3.1), T4=85.5nmol/L (66-181), TSH=3.930 uIU/mL (0.27-4.20). Her USG abdomen was showing moderate hepatomegaly with mild ascites. The ECG showing peaked P wave in lead II and upright t wave in lead V1 The echocardiography showing Mitral valve-opening and closing click present, PG:MG ratio is 8:4 ;v max is 1.4 m/s

Severe TR (non coapting tricuspid valve) RVSP 35+5 Highly dilated right atrium (13\*12 cm).

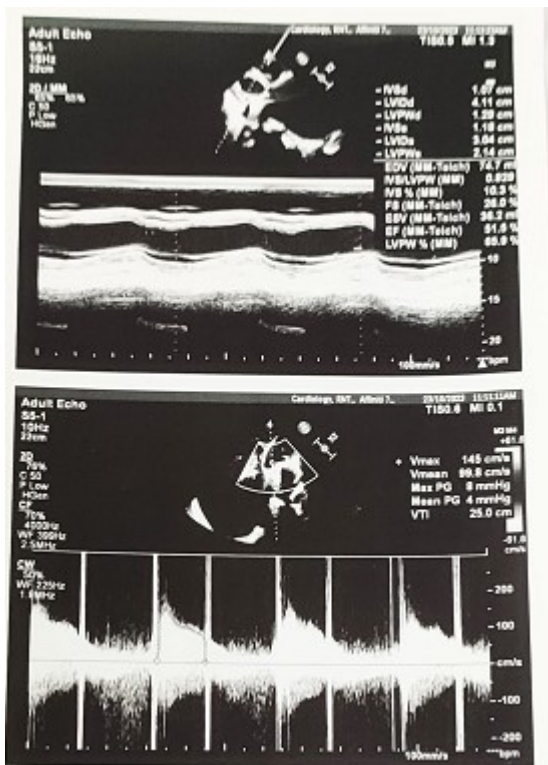


Fig.1. Showing tricuspid valve with regurgitation wave of blood from RV to RA

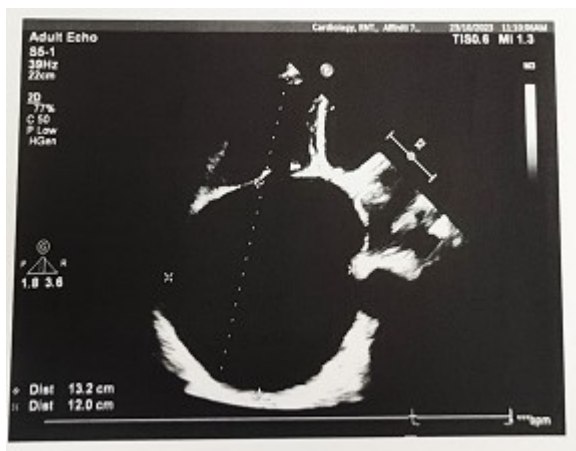

Fig. 2. Echocardiography of Right atrium showing abnormality dilated 13\*12 cm size

## DISCUSSION

The prevalence of rheumatic heart diseases is common in central and western part of India. The most common valve abnormality in RHD is mitral stenosis that would progress as a result of delayed treatment. In severe cases, when critical stenosis develops it will cause back pressure in LA and further in pulmonary artery. As pulmonary artery pressure increases, it is reflected in raised pressure in RV and that will lead to TR and increased enddiastolic blood volume in RA. If MS is not addressed at the right time then it will lead to dilated RA due to TR. Sometimes, even addressed with surgical treatment latent valve abnormality can cause progressive TR and enlarged RA. To diagnose at the right time, it is required to take proper history and detailed physical examination. In any patient presented with edema thoroughly CVS examination should be done including chest auscultation and ECG interpretation. Finding suggestive of any valve abnormality should be confirmed by echocardiography.

## CONCLUSION

In our study, an abnormally dilated RA is a rare finding in a patient of mitral valve replacement after mitral stenosis. Careful diagnosis and proper use of diuretics and routinely visit to cardiologist for maintenance and echocardiography as and when required is essential part of the treatment.

## REFERENCES

- Bayés de Luna A, Goldwasser D, Fiol M, et al. 2017. Surface electrocardiography. In: Fuster V, Harrington RA, Narula J, Eapen ZJ. eds. *Hurst's The Heart*, 14e. McGraw Hill; Accessed 8/5/2022.
- Davies, A, Scott, A. 2015. Chamber Abnormalities. In: *Starting to Read ECGs*. Springer, London. Accessed 8/5/2022.
- Harrigan RA, Jones K. 2002. ABC of clinical electrocardiography. Conditions affecting the right side of the heart (<https://pubmed.ncbi.nlm.nih.gov/12016190/>). *BMJ*. May 18;324(7347):1201-4. Accessed 8/5/2022.
- National Heart, Lung, and Blood Institute. What the Heart Looks Like (<https://www.nhlbi.nih.gov/health/heart/anatomy>). Accessed 8/5/2022.
- Zhang J, Zhang L, He L, et al. 2021. Clinical Presentation, Diagnosis, and Management of Idiopathic Enlargement of the Right Atrium: An Analysis Based on Systematic Review of 153 Reported Cases (<https://pubmed.ncbi.nlm.nih.gov/33242857/>). *Cardiology*.146(1):88-97. Accessed 8/5/2022.

\*\*\*\*\*