



ISSN: 0975-833X

Available online at <http://www.journalcra.com>

INTERNATIONAL JOURNAL
OF CURRENT RESEARCH

International Journal of Current Research

Vol. 16, Issue, 04, pp.27885-27887, April, 2024

DOI: <https://doi.org/10.24941/ijcr.47066.04.2024>

RESEARCH ARTICLE

AN UNUSUAL PRESENTATION OF LEAK AFTER SLEEVE GASTRECTOMY MANAGED BY ENDO LAPAROSCOPY – A CASE REPORT

¹Dr. Mushtaq Chalkoo, ²Dr. Yaser Hussain Wani, ³Dr. Mohd Yaqoob Bhat, ⁴Dr. Gulam Nabi Guroo, ⁵Dr. Suhaib Bashir and ⁶Dr. Naeem Ahmad

¹Professor, Department of General and Minimal Access Surgery, Government Medical College, Srinagar
²Senior Resident, Department of General and Minimal Access Surgery, Government Medical College, Srinagar
³FNB Resident, Department of General and Minimal Access Surgery, Government Medical College, Srinagar
⁴Post Graduate Resident, Department of General and Minimal Access Surgery, Government Medical College, Srinagar; ⁵Post Graduate Resident, Department of General and Minimal Access Surgery, Government Medical College, Srinagar; Post Graduate Resident, Department of General and Minimal Access Surgery, Government Medical College, Srinagar

ARTICLE INFO

Article History:

Received 20th January, 2024

Received in revised form

19th February, 2024

Accepted 15th March, 2024

Published online 30th April, 2024

Key words:

Aparoscopy

Pneumoperitoneum, Leak.

*Corresponding author:

Dr. Mushtaq Chalkoo

ABSTRACT

Laparoscopic sleeve gastrectomy is the most common bariatric surgery procedure performed worldwide. Laparoscopic sleeve gastrectomy is simple and effective procedure for weight reduction and comorbidity resolution, however complications can occur with this procedure which can be very serious. We present a case of a 45 year old male with hypertension and OSA as comorbidity who underwent an uneventful laparoscopic sleeve gastrectomy, but presented with delayed leak after four weeks which was managed by endo-laparoscopy.

Copyright©2024, Mushtaq Chalkoo et al. This is an open access article distributed under the Creative Commons Attribution License, which permits unrestricted use, distribution, and reproduction in any medium, provided the original work is properly cited.

Citation: Dr. Mushtaq Chalkoo, Dr. Yaser Hussain Wani, Dr. Mohd Yaqoob Bhat, Dr. Gulam Nabi Guroo, Dr. Suhaib Bashir and Dr. Naeem Ahmad. 2024. "An Unusual presentation of leak after sleeve gastrectomy managed by Endo laparoscopy – A case report". *International Journal of Current Research*, 16, (04), 27885-27887.

INTRODUCTION

Obesity is one of the world's major healthcare issues of the 21st century. It and its comorbidities remains a priority public health issue for most countries worldwide ⁽¹⁾. The most common bariatric surgery procedure performed both globally and in the United States is the laparoscopic sleeve gastrectomy (LSG) accounting for up to 60% of all bariatric procedures ^(2, 3). Ren et al. were the first to perform a sleeve gastrectomy laparoscopically in 1992 ⁽⁴⁾. Owing to an increase in bariatric surgical procedures, bariatric surgeons should have an understanding of the complications associated with LSG and an approach to deal with them. Early postoperative complications associated with LSG that need to be identified urgently include bleeding, staple line leak and development of an abscess. Delayed complications include strictures, nutritional deficiencies and gastroesophageal reflux disease. We will discuss the unusual presentation of a post-operative leak in one of our patients.

CASE REPORT

A 45 year old male with a BMI of 38kg/m², hypertension and Obstructive sleep apnoea (OSA) as comorbidities came to our hospital for metabolic surgery. After taking detailed history and doing relevant examination, patient was subjected to necessary investigations. His upper GI endoscopy was normal. Laparoscopic sleeve gastrectomy was performed upon this patient after taking proper consent and per operative preparation. Sleeve gastrectomy was performed by using endo GI stapler with first green and subsequent blue Cartridges. The intra operative period, hospital stay remained uneventful. The patient was discharged on liquid diet and was doing well for the initial four weeks. After four weeks, he presented to us with fever and pain in the left upper quadrant. The patient was admitted and ultrasonography of the abdomen was done, which showed peri-splenic collection of 190cc, his blood counts showed marked leucocytosis

(17,000/cumm) and raised C reactive protein. CT guided pigtail drainage of the pus collection was done. The patient underwent CECT with oral contrast, revealing a leak below the surgical gastroesophageal junction (Figure 1).

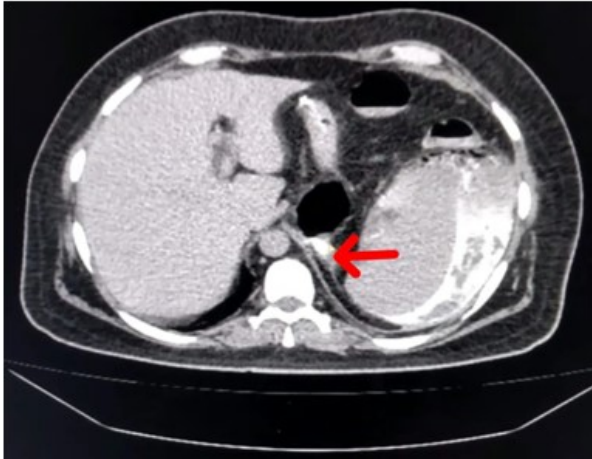


Figure 1. Leak (red arrow) on CECT with Oral Contrast

The case was discussed with the radiologist and gastroenterologist and plan of combined endo-laparoscopy was taken. The patient underwent diagnostic laparoscopy which showed normal peritoneal cavity, however there was omental wrapping in the peri-Splenic area (Figure 2), which was not disturbed.

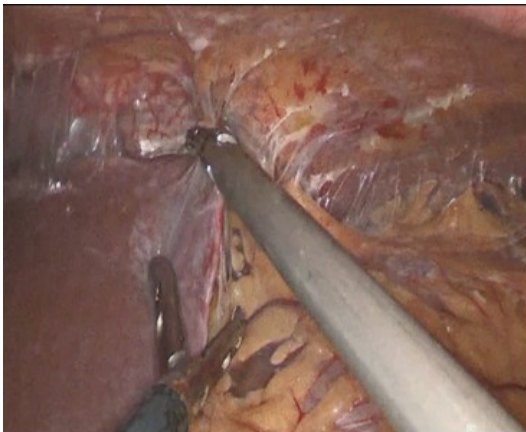

Figure 2. Laparoscopic view shows adhesions/ omental wrapping

At this point, an endoscope was introduced, identifying about 1.5 cm rent in the right lateral wall of the oesophagus just above the gastroesophageal junction (Figure 3).

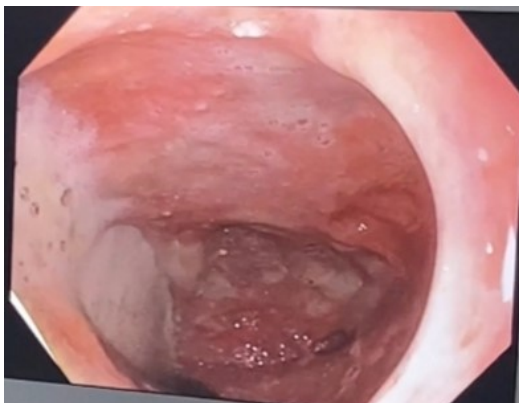

Figure 3. Endoscopic view shows Rent below GE junction

The whole suture line was examined, which was normal. The scope was then negotiated through the rent into the posterior mediastinum, where a collection was present (Figure 4).

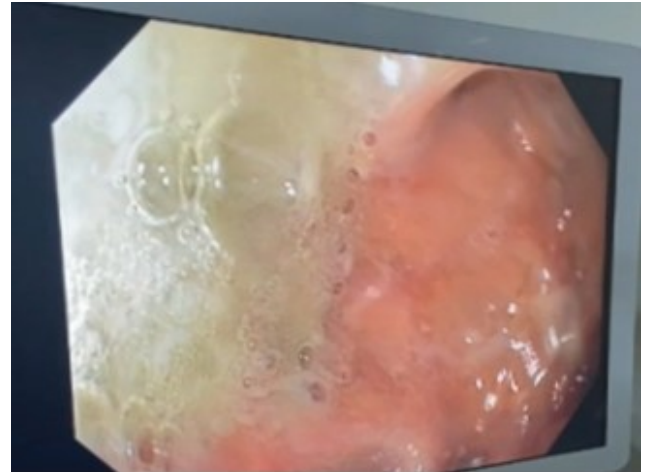


Figure 4. Collection drained through Rent

The collection was drained, and an oesophageal stent (Figure 5) was placed under fluoroscopic guidance (Figure 6). Orals were started after three days of stenting. The stent was removed after three months by endoscopy. The patient is doing well and is on follow-up.




Figure 5. Stent placed Endoscopically

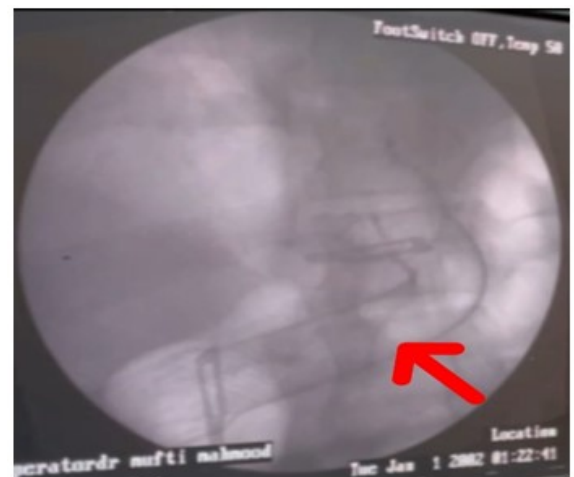

Figure 6. Fluoroscopic confirmation of Endoscopic Stent (red arrow) deployment

DISCUSSION

Leak after Laparoscopic sleeve gastrectomy occurs in 1 – 3% of patients undergoing surgery first time where as its incidence increases upto 10% who underwent revision surgery⁽⁵⁾. While leaks can occur anywhere along the staple line, they mostly do so right below the gastroesophageal junction in 85% of cases⁽⁶⁾. This is likely owing to increased intra-gastric pressure due to decreased peristalsis and ischaemia. The occurrence of leaks following LSG is linked to both coexistence of the metabolic syndrome , particularly type 2 diabetes as well as the modification of the surgical technique (over sewing the staple line, distance of the first staple fire from the pylorus and the size of gastric tube⁽⁷⁾. Male gender and BMI >50kg/m² are associated with significantly higher leak rates (2.5 vs 1.6%, p=0.02 and p < 0.01)⁽⁸⁾ however, an increase in the risk of developing fistulas and leaks is seen with smoking, improper post-operative diet, use of corticosteroids, and immunosuppressive treatment⁽⁹⁾

Based on radiologic findings and the time of diagnosis, there are many classifications⁽¹⁰⁾.the gastric leak can be divided into two categories based on the upper gastrointestinal contrast examination results. Management of a type I or subclinical leak involves inserting a surgical drain or a fistulous tract into the chest or abdomen. However, in type II or clinical leak, there is a contrast diffusion into the chest or abdominal cavities⁽¹¹⁾.Gastric leaks can also be characterized as early or late, depending on when they are diagnosed. A delayed leak is typically detected more than 8 days after surgery, whereas an early leak is typically detected within the first 3 days following surgery⁽¹²⁾. Ours being more than 4 weeks later is unusual.

CONCLUSION

Due to the constantly growing number of obese people worldwide, the number of bariatric surgery procedures has been rising accordingly. As with any surgical intervention laparoscopic sleeve gastrectomy is associated with the risk of post-operative complications. A basic understanding of common complications and available treatment options is essential for all bariatric surgeons.

REFERENCES

1. Finucane MM, Stevens GA, Cowan MJ, et al. National, regional, and global trends in body-mass index since 1980: systematic analysis of health examination surveys and epidemiological studies with 960 country-years and 9·1 million participants. *Lancet* 2011; 377: 557–67
2. Angrisani L, Santonicola A, Iovino P, et al. IFSO Worldwide Survey 2016: Primary, Endoluminal, and revisional procedures. *Obes Surg*. 2018; 28(12): 3783-3794
3. Campos GM, Khoraki J, Browning MG, Pessoa BM, Mazzini GS, Wolfe L. Changes in utilization of bariatric surgery in the united states from 1993 to 2016. *Ann Surg*. 2020;271(2):201-209
4. CJ, Patterson E, Gagner M. Early results of laparoscopic biliopancreatic diversion with duodenal switch: a case series of 40 consecutive patients. *Obes Surg* 2000;10:514-23
5. Abou Rached A, Basile M, El Masri H. Gastric leaks post sleeve gastrectomy: review of its prevention and management. *World J Gastroenterol* 2014;20:13904-10
6. D' Ugo S, Gentileschi P, Benavoli D, et al. Comparative use of different techniques for leak and bleeding during laparoscopic sleeve gastrectomy: a multicenter study. *Surg Obes Relat Dis* 2014; 10:450-4
7. Parikh M, Issa R, McCrillis A, et al. Surgical strategies that may decrease leak after laparoscopic sleeve gastrectomy: a systematic review and meta-analysis of 9991 cases. *Ann Surg* 2013; 257:231-7
8. Benedix F, Benedix DD, Knoll C, et al. Are there risk factors that increase the rate of staple line leakage in patients undergoing primary sleeve gastrectomy for morbid obesity? *Obes Surg* 2014; 24: 1610-6
9. Alizadeh RF, Li S, Inaba C, et al. Risk factors for gastrointestinal leak after bariatric surgery: MBASQIP analysis. *J Am Coll Surg* 2018;227:135-41
10. Burgos AM, Braghetto I, Csendes A, et al. Gastric leak after laparoscopic-sleeve gastrectomy for obesity. *Obes Surg* 2009; 19:1672-7
11. Csendes A, Diaz JC, Burdiles P, et al. Classification and treatment of anastomotic leakage after extended total gastrectomy in gastric carcinoma. *Hepatogastroenterology* 1990;37:174-7
12. Csendes A, Burdiles P, Burgos AM, et al. Conservative management of anastomotic leaks after 557 open gastric bypasses. *Obes Surg* 2005;15:1252-6
