



ISSN: 0975-833X

Available online at <http://www.journalcra.com>

INTERNATIONAL JOURNAL  
OF CURRENT RESEARCH

International Journal of Current Research

Vol. 16, Issue, 05, pp.28201-28203, May, 2024

DOI: <https://doi.org/10.24941/ijcr.47209.05.2024>

## RESEARCH ARTICLE

### HYDATID CYST OF THE THIGH: A CASE REPORT WITH LITERATURE REVIEW

**\*Dr. Sajad Nazir Malla, Dr. Asif Mehraj, Dr. Waseem Ul Rahman dar and  
Dr. Sheikh Bisma Ramzan**

Post Graduate, Scholar, Government Medical College, Srinagar

#### ARTICLE INFO

##### Article History:

Received 10<sup>th</sup> February, 2024

Received in revised form

15<sup>th</sup> March, 2024

Accepted 24<sup>th</sup> April, 2024

Published online 20<sup>th</sup> May, 2024

##### Key words:

Hydatid Thigh.

#### ABSTRACT

Hydatid disease (HD) is due to infection by tapeworm *Echinococcus granulosus* in its larval or cyst stage. The tapeworm lives in canids which are infected by eating the viscera of sheep that contain hydatid cysts. Most of cysts are found in liver, lungs, spleen brain and bones. The localization of hydatid cyst in muscle is rare (0.7-0.9%), even in endemic countries. Muscle hydatidosis is rare, possibly because of muscle lactic acid content and muscle contraction, two factors that likely prevent cyst growth in striated muscle. Herein we report a case of muscular hydatidosis, with concomitant hydatid liver in a 43 year female who is a known case of systemic sclerosis

##### \*Corresponding author:

**Dr. Sajad Nazir Malla**

Copyright©2024, Sajad Nazir Malla et al. This is an open access article distributed under the Creative Commons Attribution License, which permits unrestricted use, distribution, and reproduction in any medium, provided the original work is properly cited.

Citation: Dr. Sajad Nazir Malla, Dr. Asif Mehraj, Dr. Waseem Ul Rahman dar and Dr. Sheikh Bisma Ramzan. 2024. "Hydatid cyst of the thigh: A case report with literature review". *International Journal of Current Research*, 16, (05), 28201-28203.

## INTRODUCTION

Hydatid disease (HD) is due to infection by tapeworm *Echinococcus granulosus* in its larval or cyst stage. The tapeworm lives in canids which are infected by eating the viscera of sheep that contain hydatid cysts. Most of cysts are found in liver, lungs, spleen brain and bones. The localization of hydatid cyst in muscle is rare (0.7-0.9%), even in endemic countries. Muscle hydatidosis is rare, possibly because of muscle lactic acid content and muscle contraction, two factors that likely prevent cyst growth in striated muscle. Herein we report a case of muscular hydatidosis, with concomitant hydatid liver in a 43year femalewho is a known case of systemic sclerosis.

#### CASE PRESENTATION

A 43 year old female, known case of systemic sclerosis, from rural area presented to our OPD as case of painless swelling in right upper thigh from last 2 months. She is on treatment for systemic sclerosis. There is no history of any surgery in past. On examination, there was no evidence of any swelling on inspection. However, on deep palpation soft cystic swelling felt in right upper thigh, non-tender fixed in antero-medial aspect measuring approximately 6×7cm.

On ultrasonography abdomen, pelvis and thigh; Liver shows 62×66 mm well defined area with calcification, septations and cystic area inside segment 8. Gallbladder is transonic. Right thigh shows evidence of defined predominantly solid, hypo echoic lesion noted in right thigh beneath the superficial adductor muscle (intermuscular plane). The lesion has internal collapsedmembrane. No internal vascularity. On computed tomography, there is an evidence of a large cystic lesion measuring 8.7×5.1×5cm seen in segment 8 of liver with multiple daughter cysts within.

The lesion is seen sub capsular location, closely related to supra hepatic IVC, however no invasion seen. No IHBR dilated. Similar cystic lesion with multiple daughter cysts within is seen in adductor compartment of right thigh measuring 7×2.7×4.4cm. Under general anesthesia, we performed complete enucleation of right thigh hydatid cyst along with hydatid cystectomy of liver cyst with omentopexy. We opened the thigh cyst which contained about 40 to 50 daughter cysts. Histopathological examination confirmed hydatid cysts.

**Follow up and outcomes:** Post-operative, patient was managed in ward and put on albendazole 400mg bd for two months.

## DISCUSSION

The prevalence of muscular HDs is not well determined; it has been postulated that it is around 2%. Musculoskeletal HDs could be secondary or primary.

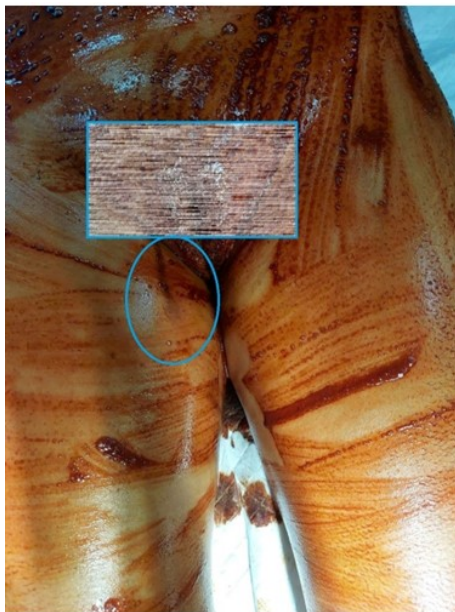


Fig 1. Swelling at anteriomedial aspect of right thigh (circled area)

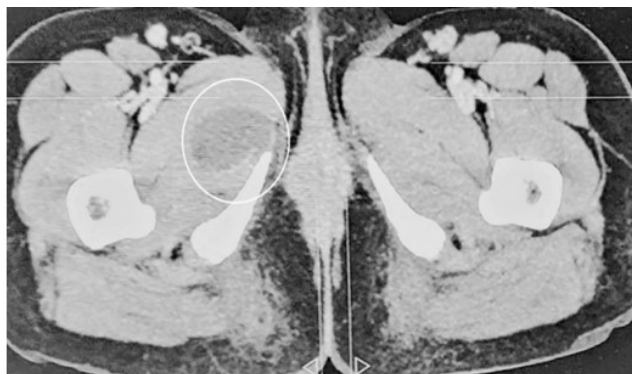


Fig 2. CT showing a cystic lesion in right thigh (circled)

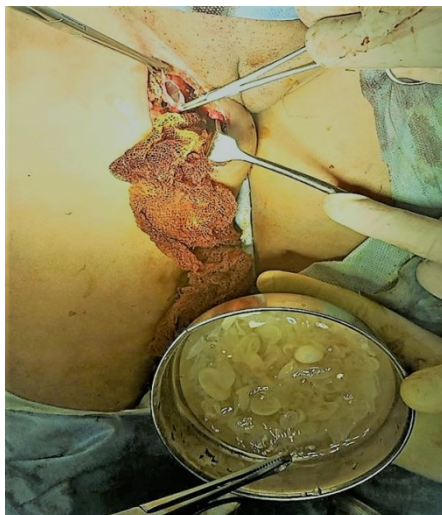

Fig 3. Intraoperative view, showing hydatid cyst thigh with daughter cysts

In the former type, HC should be reported in at least one of the common sites of HD like liver, lung or spleen. In our study, hydatid cysts (HCs) were found both in liver (segment 8) and right thigh (anteriomedial aspect in intermuscular plane). In endemic regions, HD can be controlled by several preventive mechanisms including regular medication of definitive hosts by praziquantel, vaccinating sheep, preventing dog's access to inter-mediate hosts, boiling or safe disposal of offal. Our case reported positive history of animal contact (sheep) without fulfilling any preventive measure. Up to date, 17 cases of HD of the thigh have been reported in the literature. The unique character of HD in any area of the body is that the worm can stay silently for a long period of time (months to decades) without causing specific symptom. Either it is diagnosed incidentally or causing pressure symptoms making the victim seek medical advice. The HC in this case resulted in swelling in thigh. Preoperative diagnosis of subcutaneous HD is crucial. Sensitivity of serological tests depends on the type of HD which is positive in 90% of the patients with hepatic hydatidosis while negative in the most of the HD in other areas of the body. In atypical cases, ultrasound can diagnose HDs with 100% sensitivity and specificity. Computed tomography (CT) scan gives a clearer image regarding number, site, size and architecture of the cysts also their relationship with the neighboring structures. However, in atypical HDs like muscular or subcutaneous hydatidosis, MRI is the diagnostic tool of choice because of detailed information about soft tissue structure and relationship. In the current case, ultrasound of the pelvic and left upper thigh showed features suspicious for hydatidosis. Computed tomography imaging confirmed the diagnosis of intermuscular thigh HD. Surgical resection is the definitive management strategy. The hydatid cysts in this case were managed under general anesthesia by performing complete enucleation of right thigh hydatid cyst along with hydatid cystectomy of liver HD with omentopexy.

## REFERENCES

1. Ahmed, A.E. A solitary primary subcutaneous hydatid cyst in the thigh: a case report, *Int. Surg. J.* 3 (1) (2016) 411–414.
2. Abebe, A.A. Hydatid cyst of the left thigh: a case report, *East Cent. Afr. J. Surg.* 15 (1) (2010) 139–140.
3. Argy, N. A. AbouBacar, C. Boeri, C. Lohmann, A.W. Pfaff, Y. Hansmann, et al., Primary musculoskeletal hydatid cyst of the thigh: diagnostic and curative challenge for an unusual localization, *Can. J. Infect. Dis. Med. Microbiol.* 24 (3) (2013) 99–101.
4. Bansiwala, R.K. R. Sharma, A.K. Attri, A large primary hydatid cyst of thigh: a case report, *Indian J. Surg.* 73 (2) (2011) 158–160.
5. Barkati, S. G. Butler-Laporte, M. Ndao, O.K. Ajise, M. Semret, C.P. Yansouni, et al., A recurrent hydatid cyst of the thigh diagnosed 13 years after initial presentation, *ID Cases* 11 (2018) 12–15.
6. Duygulu, F. S. Karaoglu, N. Erdogan, O. Yildiz, Primary hydatid cyst of the thigh: a case report of an unusual localization, *Turk. J. Pediatr.* 48 (3) (2006) 256.
7. Garagnani, L. A. Sudanese, E. Rimondi, P. Bacchini, Primary hydatid cyst of the root of the thigh: a case report and review of the literature, *La Chirugiadegliorgani di movimento* 92 (2) (2008) 113–118.

8. Goel, A. N.K. Dewanda, Hydatid cyst of thigh: a rare presentation, *J. Evol. Med.Dent. Sci.* 2 (40) (2013) 7761–7764
9. Gupta, A. R.P. Singal, S. Gupta, R. Singal, Hydatid cyst of thigh diagnosed onultrasonography—a rare case report, *J. Med. Life* 5 (2) (2012) 196.
10. Kazmi, Z. S. Qureishi, M.S. Quraishy, F.A. Mallick, S. Rizvi, Atypical presentation of hydatid cyst in the thigh, *J. Coll. Phys. Surg.* 27 (1) (2017) 51–52.
11. Pathak, T.K. S. Roy, S. Das, A. Achar, A.K. Biswas, Solitary hydatid cyst in thigh without any detectable primary site, *JPMA—J. Pak. Med. Assoc.* 61 (12) (2011) 1244.
12. Landolsi, M. S. Kouki, A. Abdennadher, Hydatid cyst of the thigh: a challenging diagnosis, *BMJ Case Rep.* 1 (1) (2017) 1–2.
13. Madhar, M. A. Aitsoultana, R. Chafik, H. Elhaoury, H. Saidi, T. Fikry, Primary hydatid cyst of the thigh: on seven cases, *Musculoskelet. Surg.* 97 (1) (2013) 77–79.
14. Mourafiq, O. A. Echchaoui, B. Chafri, A.S. Bouabid, D. Benchebba, M. Boussouga, Primary hydatid cyst: an unusual cause of a mass in the thigh, *BMH Med. J.* 4 (4) (2017) 139–141.
15. Perelman, H. L. Gottlieb, Hydatid cyst in muscle of the thigh, *Calif. Med.* 94 (2) (1961) 101.
16. Sarda, D.K. S.J. Lohiya, V.G. Jawandiyaa, A.T. Kamble, Migration of retroperitoneal hydatid cyst into the thigh: a rare presentation, *Indian J. Surg.* 68 (5) (2006).
17. Shaikh, R. Primary musculoskeletal hydatid cyst of thigh, *J. Islamabad Med.Dent. Coll.* 6 (2) (2017) 113–115.

\*\*\*\*\*