



ISSN: 0975-833X

Available online at <http://www.journalcra.com>

INTERNATIONAL JOURNAL  
OF CURRENT RESEARCH

International Journal of Current Research

Vol. 16, Issue, 06, pp.28693-28697, June, 2024

DOI: <https://doi.org/10.24941/ijcr.47344.06.2024>

## RESEARCH ARTICLE

### TO EVALUATE THE COMPARISON OF LIP PRINTS, PALATAL RUGAE PATTERN AND DERMATOGLYPHIC PATTERNS IN DIFFERENT SAGITTAL SKELETAL RELATIONSHIPS IN HIMACHALI POPULATION

Dr. Akshay Sharma, Dr. Anil Singla, \*Dr. Harupinder Singh Jaj, Dr. Vivek Mahajan, Dr. Indu Dhiman and Dr. Shikha Thakur

Department of Orthodontics and Dentofacial Orthopaedics, Himachal Dental College, Sundernagar, Himachal Pradesh

#### ARTICLE INFO

##### Article History:

Received 20<sup>th</sup> March, 2024

Received in revised form

15<sup>th</sup> April, 2024

Accepted 24<sup>th</sup> May, 2024

Published online 25<sup>th</sup> June, 2024

##### Key words:

Lip Prints, Dermatoglyphic Patterns, Rugae Pattern, Skeletal Relationship.

##### \*Corresponding author:

Dr. Harupinder Singh Jaj

Copyright©2024, Akshay Sharma et al. This is an open access article distributed under the Creative Commons Attribution License, which permits unrestricted use, distribution, and reproduction in any medium, provided the original work is properly cited.

Citation: Dr. Akshay Sharma, Dr. Anil Singla, Dr. Harupinder Singh Jaj, Dr. Vivek Mahajan, Dr. Indu Dhiman and Dr. Shikha Thakur. 2024. "To evaluate the comparison of lip prints, palatal rugae pattern and dermatoglyphic patterns in different sagittal skeletal relationships in Himachali population". *International Journal of Current Research*, 16, (06), 28693-28697.

#### ABSTRACT

**Introduction:** Dermatoglyphics analysis proven to be useful preliminary diagnostic investigation aid in conditions with a suspected genetic base. Palatal rugae serves as a stable landmark and are formed during similar time of intrauterine life as the teeth, so one can assume the relationship exist between the two. Similarly the lip prints are also unique to an individual just like fingerprints and shows a strong hereditary pattern. **Aims and Objectives:** To evaluate the comparison of Lip prints, Palatal rugae pattern and Dermatoglyphic Patterns in different sagittal skeletal relationships. **Materials and Methods:** A total of 90 patients, aged 12-18 years, were selected from those who attended the outpatient clinic of the Department of Orthodontics and Dentofacial Orthopaedics. The patients were divided into 3 groups as Class I, Class II, and Class III based on ANB angle. Palatal rugae, fingerprints and lip prints were recorded based on patterns in each group, then compared. **Results:** The correlation of vertical lip pattern with skeletal class III malocclusion was found. The wavy rugae pattern was most common in all skeletal groups. There was increased distribution of whorl pattern in the skeletal Class II and increased distribution of loop pattern in the skeletal Class III. **Conclusion:** A significant correlation was found between vertical lip pattern and skeletal class III malocclusion, and current study showed no specific palatal rugae pattern among the sagittal classes of skeletal malocclusion. There was significant correlation of whorl pattern in the skeletal Class II and loop pattern in the skeletal Class III.

## INTRODUCTION

Dermatoglyphic analysis are very useful in the initial investigation of suspected genetic conditions. There are many evaluations regarding hard and soft tissues, where lips, rugae and dermatoglyphic patterns play an important role in planning orthodontic treatment.<sup>1</sup> Dermatoglyphic patterns are unique to each person and are determined by small changes in local environment of the fetus and remains unchanged throughout life.<sup>2</sup> In dentistry, patients with periodontitis, dental caries and cleft lip and palate have different finger patterns are also associated with skeletal malocclusion.<sup>3</sup> Lip prints contain fissures and lines in form of grooves and wrinkles. Grooves and wrinkles are located in the area between the inner mucosa and the outer skin of the lips. The study of examination of lip prints is referred to as Cheiloscopy.

Different studies have shown that lip prints can be used for identification and also for the investigation of crimes in forensic dentistry.<sup>4</sup> Palatal rugae are small ridges located in front of the hard palate and are unique to each person. These are anatomical folds of the oral mucosa located in the anterior third of the palate, behind the incisive papillae on both sides, and vary from person to person. Various studies have shown a relationship between this change and rugae patterns and skeletal malocclusion.<sup>5</sup> However, there were very few studies in Himachal Pradesh to determine the lips, rugae and dermatoglyphic patterns of people with different skeletal relationships. Therefore the objective of this study was to evaluate the comparison of Lip prints, Palatal rugae pattern and Dermatoglyphic Patterns in different sagittal skeletal relationships in Himachali population.

## MATERIALS AND METHODS

The research was carried out in the Department of Orthodontics and Dentofacial Orthopaedics. Informed consent was acquired from the patient or parent/guardian. This study received ethical approval from the Institutional research ethical committee. 90 patients who wanted to receive dental treatment in the orthodontics department were incorporated in the study. (n=90)

Patients were distributed into 3 groups:

**Group 1:** Skeletal class I, ANB between 0 and 4 degrees. (n=30)

**Group 2:** Skeletal class II, ANB more than 4 degrees (n=30).

**Group 3:** Skeletal class III, ANB 0 or negative (n=30).

The selected patients consisted of healthy individuals who agreed to participate in the study and individuals who had not received treatment before. Patients with injuries, systemic diseases, developmental disorders, mental disabilities, and those without informed consent were excluded from the study.

### Methodology

**Method to record lip prints:** To take lip prints, lip cellophane technique was used in this study.<sup>4</sup> The patients were asked to sit in the dental chair in a comfortable position. Then, cut off some of the red lipstick with the Bard Parker knife, put it on the dappen dish and apply it to lips of patient with the lip brush. Place the sticky end of the transparent tape on the lips, gently tap the middle first, and then press evenly to the corners of the lips. For permanent recordings, the transparent tape was stuck on white paper and the lip print was viewed using a magnifying glass as shown in Figure 1.

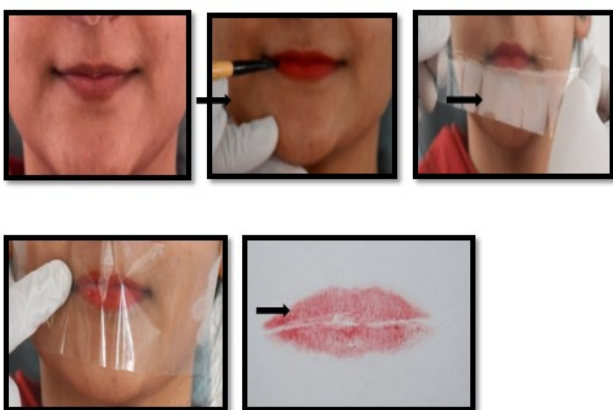


Figure 1. Method to record lip prints

The categorization of lip print patterns as proposed by Tsuchihashi<sup>6</sup>, was followed which was shown in Figure 2 and Table I.

**Fingerprint printing method:** To record fingerprints the ink stamp method was used.<sup>2</sup> The patients were asked to clean their hands with soap and wipe them with ethanol to remove sweat, oil, and dirt from the skin.

Then roll the dried phalanges of both the hands on stamp pad and then stamped on bond paper which was held in place with tape as shown in Figure 3. The classification of Dermatoglyphic patterns used in this study was proposed by Cummins H and Mildo C<sup>7</sup> as shown in Figure 4.

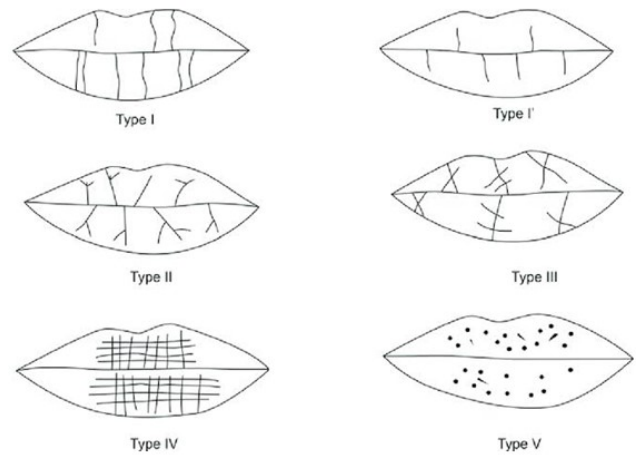


Figure 2. Classification of lip prints by tsuchihashi

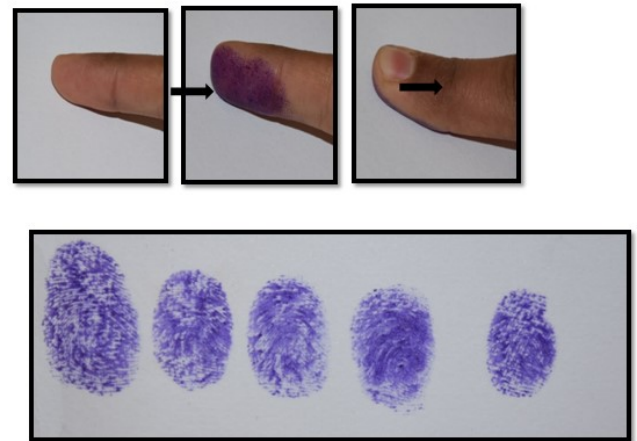


Figure 3. Method to record fingerprints

**Recording rugae pattern:** The dental casts were obtained from alginate impressions of maxillary arch. Then the ends of the rugae patterns were marked on dental cast as shown in Figure 5. The classification of rugae patterns used in this study was given by Hauser et al<sup>8</sup> as shown in Table II and Figure 6.

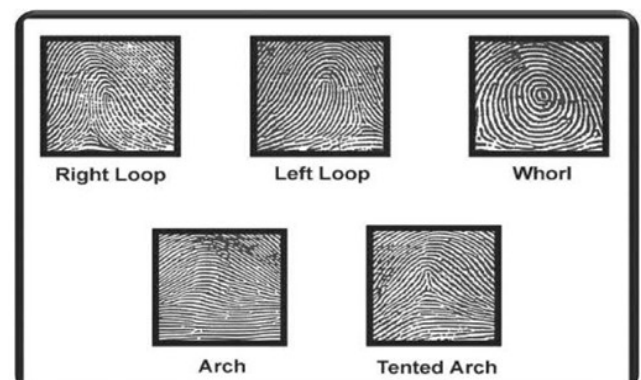


Figure 4. Classification of fingerprint pattern by Cummins h and mildo c

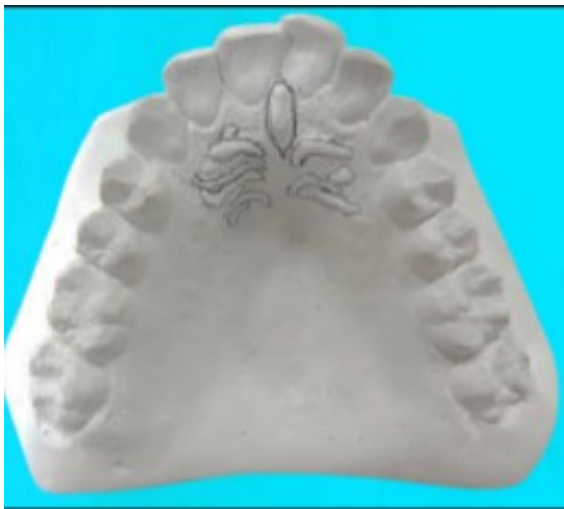

Figure 5. Method to record the rugae pattern

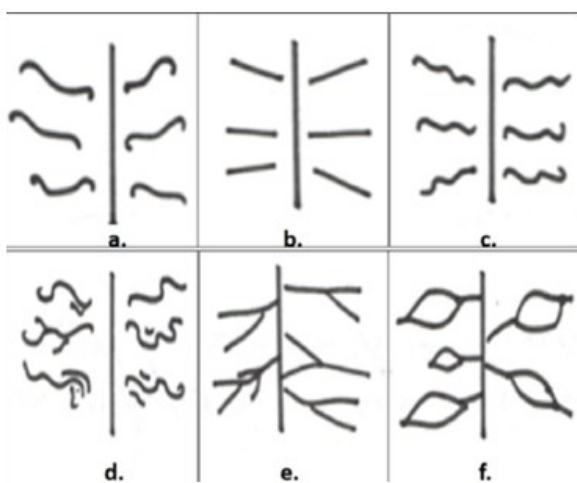


Figure 6. Classification of Rugae pattern: a) curved b)straight c)wavy d)irregular e)forking f) island

**Method errors:** To evaluate the errors lips, rugae and dermatoglyphic patterns were evaluated twice by the same researcher, one week apart. Intra-examiner reliability was assessed using the Kappa statistic and showed excellent agreement (Kappa = 0.80-1.00,  $p < 0.001$ ). Data was analyzed using SPSS (Statistical Package for Social Sciences) software (version 21). The data obtained were analyzed using the chi-square test and Spearman's rank correlation. If correlation coefficient ( $r$ ) is more than 0, then it is positive relationship and closer the correlation coefficient ( $r$ ) to 1; stronger is the correlation. Statistical significance is  $p < 0.05$ .

## RESULTS

On comparison of lip prints in different skeletal malocclusions, the prevalence of branched lip pattern was found to be 36.6% in both skeletal class I and class II malocclusion. While the prevalence of vertical lip pattern was found to be 43.3%. The prevalence of undetermined lip pattern was found to be 6.7% in class I malocclusion, 10% in class II malocclusion and 0% in class III malocclusion as shown in Table III. The prevalence of vertical lip print pattern in subjects with class III malocclusion was more than that of class I and class II malocclusion. This study showed a strong correlation of vertical lip pattern with skeletal class III

malocclusion as shown in Table VI. On comparison of rugae patterns in different skeletal malocclusions, the prevalence of wavy rugae pattern was found to be 46.7% in both class I and class III malocclusion and 50% in class II malocclusion. The prevalence of divergent pattern was found to be 10% in class I malocclusion, 13.3% in class III malocclusion and 0% in class II malocclusion as shown in Table IV. There was no correlation found between rugae patterns and skeletal malocclusion as shown in Table VII.

Moreover, on comparison of dermatoglyphic patterns in different skeletal malocclusions, the prevalence of loop pattern was found to be 56.7% in skeletal class I malocclusion and 66.7% in skeletal class III malocclusion. The prevalence of whorl pattern was 60% in skeletal II malocclusion. The frequency of arch pattern was found to be 6.7% in both skeletal class I and class II malocclusion and 3.3% in skeletal class III malocclusion as shown in Table V. The prevalence of whorl pattern was found to be more in class II malocclusion and also the prevalence of loop pattern was more in class III malocclusion. The present study showed a strong correlation of loop pattern with the skeletal Class III malocclusion and whorl pattern with the skeletal Class II malocclusion as shown in Table VIII.

## DISCUSSION

Diagnosis of soft tissues in orthodontics includes different measurements out of them lips, rugae and dermatoglyphic patterns play an important role in diagnosis. Analysis of these soft tissue are simple, effective and non-invasive and had found application in many fields and dentistry. In dentistry, these soft tissue analysis are a useful diagnostic tool that can identify genetic factors associated with various oral diseases. Early diagnosis and correction of deviations in jaw growth patterns through early dental intervention may help prevent some future orthognathic surgeries. On evaluation of lip patterns, the results of the present study showed that branched lip pattern was most prevalent in skeletal class I and class II malocclusion (36.6%). This was in agreement with study done by Pandey A et al (2020)<sup>16</sup>. While in individuals with skeletal class III malocclusion vertical lip pattern (43.3%) was most prevalent.

And undetermined was least commonly found in all skeletal malocclusions, 6.7% in class I, 10% in class II and 0% in class III malocclusion. These results were also found in research done by Raghav P et al (2013)<sup>4</sup>. Moreover, our study showed a strong correlation of vertical lip pattern with skeletal class III malocclusion as shown in Table VI. It has been stated by many researchers, that lip prints, as well as skeletal class III malocclusion showed strong inheritable tendency. This might be possibly explaining the reason for having a significant relationship of vertical lip patterns and skeletal class III malocclusion. This was in accordance with study done by Raghav P et al. (2013)<sup>4</sup>. On comparison of rugae patterns in different skeletal malocclusions, the present study showed that wavy rugae pattern was most common in all the skeletal malocclusions, 46.7% in class I and class III and 50% in class II malocclusion and the divergent pattern was least common 10% in class I malocclusion, 13.3% in class III malocclusion and 0% in class II malocclusion as shown in Table IV. This was in accordance with study done by Azab et al (2016)<sup>11</sup>.

Table I. Classification of Lip Prints

Type I	Clear-cut vertical grooves that run across the entire lips.
Type I'	Similar to type I, but do not cover the entire lip.
Type II	Branched grooves (branching Y-shaped pattern).
Type III	Intersected grooves (criss-cross pattern, transverse grooves).
Type IV	Reticular grooves.
Type V	Undetermined (grooves do not fall into any of the type I-IV and cannot be differentiated morphologically).

Table II. Classification of Rugae Pattern

Cyclic	Specific continuous loop straight: They appear directly from their origin to the end of the rugae
Wavy	Slight curvature
Curve	Crescent with a slight curve
Irregular	Rugae's broken and irregular pattern.
Island	Circular rugae showing the formation of a distinct continuous ring at the end.
Unification	Two rugae connected at the origin or end which is divided to two category according to Kapoor et al <sup>9</sup> method.
Divergent	With the same origin that diverges quickly
Convergence	Rugae with different origins that join together

Table III. Prevalence of lip patterns

Lip pattern	Skeletal Class I		Skeletal Class II		Skeletal Class III	
	Frequency	Percentage	Frequency	Percentage	Frequency	Percentage
Branched	11	36.7	11	36.7	7	23.3
Intersected	4	13.3	8	26.7	6	20.0
Reticular	9	30.0	4	13.3	4	13.3
Undetermined	2	6.7	3	10.0	0	0
Vertical	4	13.3	4	13.3	13	43.3
Total	30	100.0	30	100.0	30	100.0

Table IV. Prevalence of palatal rugae patterns

Rugae pattern	Skeletal Class I		Skeletal Class II		Skeletal Class III	
	Frequency	Percentage	Frequency	Percentage	Frequency	Percentage
Curve	4	13.3	2	6.7	3	10.0
Divergent	3	10.0	0	0	4	13.3
Straight	9	30.0	10	33.3	9	30.0
Wavy	14	46.7	15	50.0	14	46.7
Total	30	100.0	30	100.0	30	100.0

Table V. Prevalence of dermatoglyphic patterns

Dermatoglyphic pattern	Skeletal Class I		Skeletal Class II		Skeletal Class III	
	Frequency	Percentage	Frequency	Percentage	Frequency	Percentage
Arch	2	6.7	2	6.7	1	3.3
Loop	17	56.7	10	33.3	20	66.7
Whorl	11	36.7	18	60.0	9	30.0
Total	30	100.0	30	100.0	30	100.0

Table VI. Correlation of lip patterns in different skeletal malocclusion

Lip pattern	Skeletal Class I (CORRELATION COEFFICIENT) (r)	Skeletal Class II (CORRELATION COEFFICIENT) (r)	Skeletal Class III (CORRELATION COEFFICIENT) (r)	P-value
Branched	0.092	0.088	0.098	0.88
Intersected	0.066	0.054	0.088	0.50
Reticular	0.066	0.088	0.054	0.52
Undetermined	0.012	0.014	0.086	0.62
Vertical	0.058	0.066	0.470*	0.032*

p<0.05 \* statistically significant; p<0.001\*\* statistically highly significant

Table VII. Correlation of palatal rugae patterns in different skeletal malocclusion

Rugae pattern	Skeletal Class I (CORRELATION COEFFICIENT) (r)	Skeletal Class II (CORRELATION COEFFICIENT) (r)	Skeletal Class III (CORRELATION COEFFICIENT) (r)	P-value
Curve	0.090	0.088	0.096	0.80
Divergent	0.060	0.044	0.064	0.43
Straight	0.082	0.066	0.084	0.65
Wavy	0.060	0.044	0.064	0.50

p<0.05 \* statistically significant; p<0.001\*\* statistically highly significant

**Table VIII. Correlation of dermatoglyphic patterns in different skeletal malocclusion**

Dermatoglyphic pattern	Skeletal Class I (CORRELATION COEFFICIENT) (r)	Skeletal Class II (CORRELATION COEFFICIENT) (r)	Skeletal Class III (CORRELATION COEFFICIENT) (r)	P-value
Arch	0.016	0.018	0.016	0.98
Loop	0.058	0.036	<b>0.551*</b>	<b>0.03*</b>
Whorl	0.056	<b>0.316*</b>	0.032	<b>0.04*</b>

p<0.05 \* statistically significant; p<0.001\*\* statistically highly significant

There was no correlation found between rugae patterns and skeletal malocclusion as shown in Table VI. These results were also found in study done by Rizwan N et al(2020)<sup>5</sup>. Moreover, on comparing dermatoglyphic patterns in different skeletal malocclusion, the results showed that the loop pattern was most common in skeletal class I malocclusion (56.7%) and skeletal class III malocclusion (66.7%) and whorl pattern was most common in all skeletal II malocclusion (60%). This was in agreement with study done by Sussha M et al(2017)<sup>2</sup>. Further, our study showed that there was a strong correlation of whorl pattern with the skeletal Class II as shown in Table VIII. This might be due to the fact that dermatoglyphic patterns are genetically determined so as the skeletal Class II malocclusion. These results were also found in study done by Kharbanda OP et al (1982)<sup>12</sup> and Sussha M et al (2017)<sup>2</sup>. While there was correlation of loop pattern with the skeletal Class III malocclusion as shown in Table VIII.

This might be because both skeletal class III malocclusion and dermatoglyphic patterns shows strong inheritable tendency. This was in agreement with research done by Sharma VP et al(1980)<sup>3</sup> and Belludi AC et al(2021)<sup>19</sup>. The limitation of our study was that the dental models were manually traced. Further studies with larger samples and 3D scanners are recommended to evaluate rugae patterns for better results. Larger sample size should be taken to establish a better relationship between dermatoglyphic patterns, lip prints, and sagittal differences. The recording of fingerprints with ink could cause incomplete fingerprints and many times there can be recording of smudged fingerprints. Digitalized fingerprint sensors could be useful to overcome this limitation.

## CONCLUSION

The conclusions drawn from the study were as follows

- Although the relationship between class I and II malocclusion and the lip prints were unclear, but there was a strong relationship between the vertical lip pattern and the skeletal class III malocclusion.
- The current research indicates that there was no specific palatal rugae pattern among the sagittal classes of skeletal malocclusion.
- There was significant correlation between the whorl dermatoglyphic pattern in the skeletal Class II malocclusion and loop pattern in the skeletal Class III malocclusion.

## REFERENCES

1. Graber TM. Orthodontics: Principles and practice. 2005;3:397-9.
2. Sussha M et al. An Assessment of Correlation Between Dermatoglyphic Patterns and Sagittal Skeletal

Discrepancies. *Journal of Clinical and Diagnostic Research*. 2017 Mar, Vol-11(3).

3. Sharma VP, Gupta DS, Kharbanda OP. Dermatoglyphic evaluation of retrognathism. *J Indian Dent Assoc*. 1980;52:111-14.
4. Raghav P et al. Lip prints and skeletal malocclusion *Journal of Forensic Dental Sciences / July-December 2013 / Vol 5 / Issue 2*.
5. Rizwan N, Sheikh F, Memon S, Agha D. Association of Rugae Pattern with Skeletal Malocclusion in Orthodontic Patients Visiting Tertiary Care Hospital. *Pakistan journal of medicine and dentistry 2020, VOL. 9 (03)*.
6. Tsuchihashi Y. Studies on personal identification by means of lip prints. *Forensic Sci 1974;3:233-48*.
7. Cummins H and Midlo C. Finger prints, palms and soles. An introduction to Dermatoglyphics. *Dover Publications, Inc., New York. 1961*.
8. Hauser G, Roberts MJ. Palatal rugae in Swazi, southern Africa. *AnthropolAnz 1986 1:257-61*.
9. Kapoor P, Kaur H. Rugoscopy: A Diagnostic Appurtenance for Malocclusion or just a Forensic Aid?-A Pilot Study. *J Forensic Res 2015;6:272*.
10. Hirth L, Göttsche H, Goedde HW. Lip prints: Variability and Genetics. *Humangenetik 1975;30:47-62*.
11. Azab SMS, Magdy R, El Deen MAS. Patterns of palatal rugae in the adult Egyptian population. *Egypt J Forensic Sci 2016 1;6:78-83*.
12. Kharbanda OP, Sharma V, Gupta DS. Dermatoglyphic evaluation of mandibular prognathism. *J Indian Dent Assoc*. 1982;54:179-86.
13. Maltoni D, Maio D, Jain AK, Prabhakar S. Handbook of fingerprint recognition. *Springer - Verlag. 2003*.
14. Mossey PA. The Heritability of Malocclusion: part 2. The influence of genetics in malocclusion. *Br J Orthod 1999;26:195-203*.
15. Litton SF, Ackermann LV, Isaacson RJ, Shapiro BL. A genetic study of class 3 malocclusion. *Am J Orthod 1970;58:565-77*.
16. Pandey A, Kumar N, Nabi AT, Kavita K, Choudhary P, Raj R. Correlation between lip print patterns and skeletal class I and II malocclusions – A tool to diagnose early. *J Family Med Prim Care 2020;9:3539-43*.
17. Allani S, Setty JV, Srinivasan I, et al. Determination of Relationship between Lip Prints and Skeletal Malocclusion in Children of Age 9–14 Years. *Int J ClinPediater Dent 2019;12(6):494–499*.
18. Fatima F, Fida M, Shaikh A. The association between palatal rugae pattern and dental malocclusion. *Dental Press J Orthod*. 2019 Jan-Feb;24(1):37.e1-9
19. Belludi AC, Sridhara A, Kumar NC, et al. Dermatoglyphics: A Noninvasive Diagnostic Tool in Predicting Class III Skeletal Malocclusion in Children. *Int J ClinPediater Dent 2021;14(1): 63–69*.