



## RESEARCH ARTICLE

### MAGNETIC RESONANCE IMAGING IN DIAGNOSIS OF HIP JOINT PATHOLOGY

Dr. Pintu Biswas<sup>1</sup>, Dr. Santosh Reang<sup>2</sup> and Dr. Pipavath Saritha<sup>3</sup>

<sup>1</sup>MD, Senior Resident, Department of Radiodiagnosis, Agartala Government Medical, College and GB Pant Hospital, Agartala, West Tripura; <sup>2</sup>MS, Associate Professor, Department of Orthopaedic, Agartala Government Medical College & GB Pant Hospital, Agartala, West Tripura; <sup>3</sup>Post Graduate Student, Department of Radiodiagnosis, Agartala Government Medical, College and GB Pant Hospital, Agartala, West Tripura

#### ARTICLE INFO

##### Article History:

Received 14<sup>th</sup> September, 2024  
Received in revised form  
27<sup>th</sup> October, 2024  
Accepted 20<sup>th</sup> November, 2024  
Published online 26<sup>th</sup> December, 2024

##### Key Words:

Avascular Necrosis, Hip Pathology,  
Magnetic Resonance Imaging.

\*Corresponding author:  
Pintu Biswas

#### ABSTRACT

**Introduction:** Pathologies in relation to hip joint is very common clinical problem, which requires imaging studies in addition, for which MRI is generally advised. This imaging modality is commonly used due to its excellent soft tissue contrast, multiplanar imaging capabilities with high spatial resolution. It provides excellent details of soft tissue, ligaments, cartilage, joint fluid, extraarticular soft tissues and osseous structures. **Materials and Methods:** This cross-sectional study was conducted at the Department of Radiodiagnosis at Agartala Government Medical College and GB Pant Hospital, Agartala, Tripura. A total of 65 consecutive patients were included in the study after obtaining a consent. **Result:** Out of total 65 cases, 45 were male (69.2%) and rest 20 (30.8%) were female. Age of patients ranged from 5 to 70 years. Maximum numbers of patients were in the age group of 21-30 years (21 cases – 32.3%). AVN was the most common pathology detected comprising 26 cases (40%). Osteoarthritis was second most common abnormality, detected in 10 (15.4 %) cases. Neoplastic lesions were seen in 6 cases (9.23 %). **Conclusion:** Magnetic resonance imaging (MRI) is the optimal approach for identifying hip pathologies due to its high resolution, improved tissue contrast differentiation, and multiplanar imaging capabilities.

Copyright©2024, Pintu Biswas et al. This is an open access article distributed under the Creative Commons Attribution License, which permits unrestricted use, distribution, and reproduction in any medium, provided the original work is properly cited.

Citation: Dr. Pintu Biswas, Dr. Santosh Reang and Dr. Pipavath Saritha. 2024. "Magnetic resonance imaging in diagnosis of hip joint pathology". *International Journal of Current Research*, 16, (12), 30847-30850.

## INTRODUCTION

Pathologies in relation to hip joint is one of the common clinical problem, which requires imaging studies in addition to clinical examination. The hip is one of the most important weight-bearing joint of human body. Hip joint abnormalities in the form of pain has a long list of etiologies including intraarticular, periarticular and extraarticular disorders. Apart from trauma- infection, arthritis, avascular necrosis (AVN), neoplasms, and hip dysplasia are other common causes, for which MRI is generally advised. All these condition may not manifest radiographic abnormalities in the early stages. Though collection in & around the joint space is well visualized by ultrasonography, it is unable visualize the anatomical details of hip; moreover it is operator dependent. Computed tomography can detect bony details very well, but soft tissue, ligaments, cartilages are not well appreciated. In addition in has radiation hazards. Since its introduction in diagnostic medical science, MRI has become one of the most powerful imaging modality for musculoskeletal studies.

This is the imaging modality which is commonly used due to its excellent soft tissue contrast, multiplanar imaging capabilities with high spatial resolution. In addition it is radiation free. It provides excellent details of soft tissue, ligaments, cartilage, joint fluid, extraarticular soft tissues and osseous structures (1). Despite more than two decades of experience in imaging the hip with MRI, its role as a diagnostic imaging modality in the patient with hip pain continues to evolve. Comprehensive studies involving large series of cases of pathologies involving the hip and their evaluation by MRI are not much in the Indian literature. Most of the work has been in the form of isolated case reports (2). This study emphasizes the role of MRI in the evaluation of hip pathologies at a tertiary care hospital.

## MATERIALS AND METHODS

This cross-sectional study was conducted at the Department of Radiodiagnosis at Agartala Government Medical College and

GB Pant Hospital, Agartala, Tripura over a period of 18 months from May'23 to Oct'24. All the cases with suspected hip pathology who were referred from various Departments to the Department of Radiodiagnosis of this institution for MRI of hip joint and in whom the study was done, were included in this study. A total of 65 consecutive patients were included in the study after obtaining a consent. The imaging was done using 3 tesla MRI machine with appropriate imaging protocol. The collected data were tabulated and analyzed using descriptive statistics. Statistical for the social sciences (SPSS) software (version- 15) was used for data analysis.

## RESULTS

The present study was conducted in 65 patients who underwent radiological examination at this tertiary care institute. Out of total 65 cases, 45 were male (69.2%) and rest 20 (30.8%) were female. So male to female ratio was- 2.25:1. Age of patients ranged from 5 to 70 years. Maximum numbers of patients were in the age group of 21-30 years (21 cases – 32.3%). Distribution of the cases according to the age group & gender is shown in Table 1.

**Table 1. Distribution of the cases according to the age group & gender**

Age group (years)	No of patients	Percent	Male	Female
0 - 10	3	4.6	2	1
11-20	8	12.4	7	1
21- 30	21	32.3	14	7
31- 40	14	21.5	12	2
41- 50	9	13.8	5	4
51-60	6	9.2	3	3
61- 70	4	6.2	2	2
Total	65	100	45	20

In this study, out of total 65 cases, pathology were detected in 61 cases (93.8 %). Pathological involvement was unilateral in 30 cases (46.15 %), whereas it was bilateral in 31 cases (47.69 %). In four cases (6.5%), no abnormality was detected. Avascular necrosis (AVN) was the most common pathology detected comprising 26 cases (40%). AVN was unilateral in 10 cases (38.46 %) and bilateral in 16 (61.53 %) cases. The most common stage (Ficat & Arlet) of AVN was stage- III (10 cases) (Fig. 1) followed by stage- 2 (9 cases). Among these 26 patients, 20 were male & 6 were female- hence male to female ratio for this pathology was 3.33:1. The next most common abnormality detected was osteoarthritis, found in 10 (15.4 %) cases.

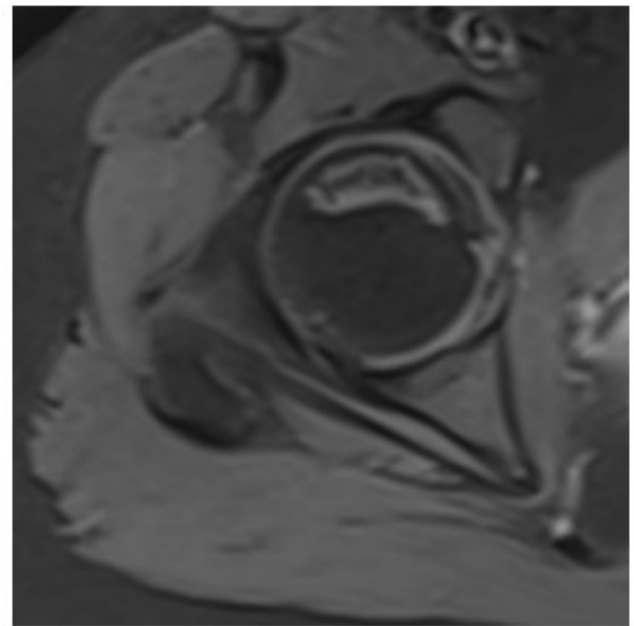
**Table 2. showing various pathologies seen in this study.**

PATHOLOGY		No of cases	Percent
Avascular necrosis		26	40
Osteoarthritis		10	15.4
Transient osteoporosis		7	10.76
Transient synovitis		3	4.6
Osteomyelitis		3	4.6
Septic arthritis		4	6.2
Perthe's disease		1	1.5
Isolated hip joint effusion		1	1.5
Neoplastic		6	9.23
1	Osteoid osteoma	1	1.5
2	Giant Cell Tumor	2	3.1
3	Metastatic	2	3.1
4	Non Ossifying Fibroma	1	1.5
Within normal limit		4	6.2
Total		65	100

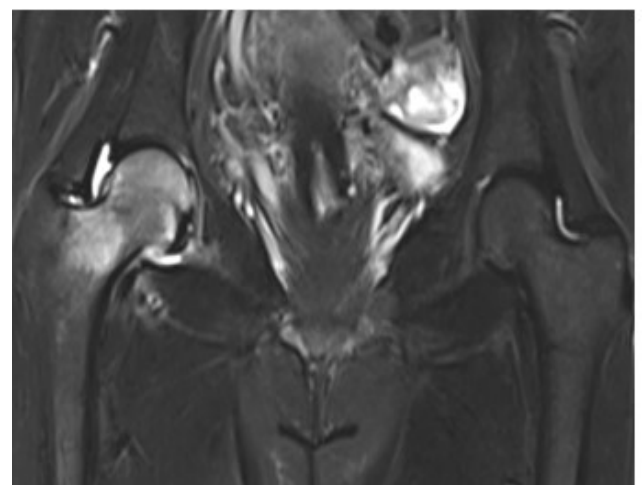
Transient osteoporosis were detected in 7 cases (10.76 %) (Fig 2), transient synovitis (Fig. 3A & 3B) in 3 cases (4.6%), osteomyelitis in 3 cases (4.6%), septic arthritis in 4 cases (6.2 %). Perthe's disease was seen in 1 case (1.5%). Isolated hip joint effusion in 1 case (1.5 %) was also noted. Total 6 neoplastic lesions were seen in this study (9.23 %).

Among these cases, Osteoid osteoma in 1 case (1.5 %), Non ossifying fibroma in 1 case (1.5 %), Giant cell tumor were seen in 2 cases (3.1%) and metastatic lesion in 2 cases (3.1 %) (Fig. 4). Table 2 is showing various pathologies detected in this study.

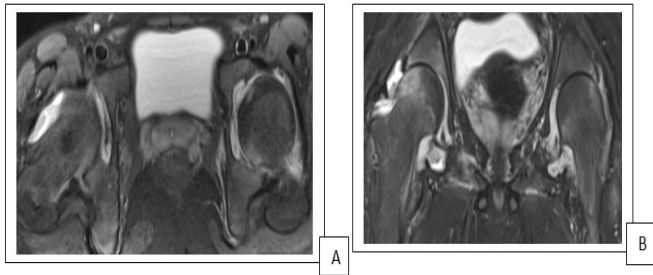
## REPRESENTATIVE IMAGES OF THIS ARTICLE



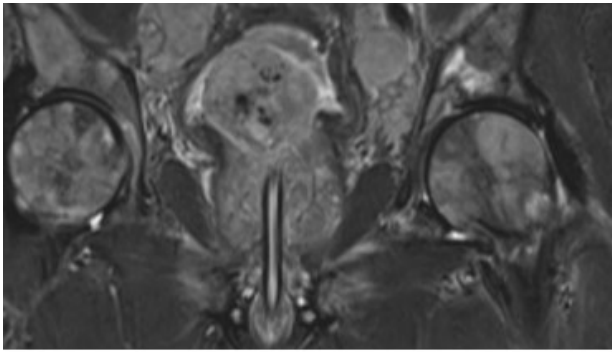
**Fig. 1. T1 weighted image showing subchondral crescentic shaped signal altered lesion involving head of right femur which appears heterogeneously hyperintense resembling crescent sign of AVN .....features suggestive of FICAT & ARLET STAGE III AVN of right femoral head**



**Fig. 2. This coronal T2 TIRM is showing evidence of high signal intensity on in the Right femoral head and neck. Also evidence of minimal peri-articular fluid-effusion seen. Articular cartilage shows normal signal intensity. A case of transient osteoporosis**



**Fig. 3. A (T2 Trans PDFS) & B (T2 Coronal):** There is evidence of thickening of synovial membrane with minimal collection in bilateral hip joints which appears hypo intense in T1 (not shown here) and hyperintense in T2 & PDFS sequences suggestive of synovitis (R>L). There is also features of right femoral head edema



**Fig. 4. Coronal T2 Tirm** showing multiple signal altered lesions seen involving Head & visible part of both femur, visible part of both ilium in a known case of ca- prostate: suggestive of bone secondaries

## DISCUSSION

We studied 65 cases, where age of patients ranged from 5 to 70 years. This sample size is almost similar to Tripathi et al, where they studied 60 patients and age ranged from 6 to 75 years (2). In this study, male to female ratio was- 2.25:1, which is similar to the study by RamBhamu et al, where they found that, the male to female ratio was 2.3:1 (3). This finding is also very close to the study by Tripathi et al, where gender ratio was 2.1 (2). In this study, unilateral involvement were in 46.15 % & bilateral in 47.69 %. In their study by Tripathi et al, unilateral involvement were in 52% & bilateral in 48 %, which is comparable to this study (2). The asymmetry in this regard is probably due to inclusion of those 4 cases, which came out to have no significant abnormality after MRI. AVN was the most common pathology detected in 40%, which is almost similar to finding of Tripathi et al (2), where it was seen in 41.6 % cases. Among AVN, 38.46 % were unilateral and 61.53 % were bilateral. AVN as the most common pathology is reported in many other studies (2, 4 - 6). Literature also reveals that unilateral & bilateral involvement in AVN ranges from 20-42 % & 14.82- 80% respectively (2, 5). Stage III (Ficat & Arlet) AVN was commonest in this study which was noted in 38.46 % (10 out of 26 cases) - which is comparable to Dahiphale et al (4), who noted in 43.75 % cases. Second most common abnormality detected was osteoarthritis, found in 15.4 % cases. Similar frequency were seen in the study by Dahiphale et al, where they observed OA in 16% cases (4). In the study by Chougule SR (7), osteoarthritis was also the second most common pathology, though higher frequency was recorded (24.07 % cases).

Slightly lower frequency were detected in the study by Rao et al (5) & Narra et al (6) as well as Venkatesh et al (8), where the frequency were 13.3 %, 8% and 11% respectively. Similar to this study, Kalekar et al (9), Reddy et al (10) and Drar et al (11) also had observed avascular necrosis as the most common pathology of hip followed by osteoarthritis. In the present study, transient osteoporosis- seen in 10.76 % cases. It is same to the observation made by Drar et al (11) where they found it in 10 % cases. Our finding is also close to other earlier studies by Dahiphale et al (4) where it was seen in 8 % cases, though in a similar study, Shourbagy et al reported transient osteoporosis in only 4 % cases (12). In this study, transient synovitis was observed in 4.6% cases, which is comparable to the study by Ram et al, where it was seen in 3.75 % cases (13), although higher values (8 % & 10 %) have been reported in few other journals (4, 14). Osteomyelitis were seen in 4.6 % cases in this study. Slightly lower frequency (1.8 %) was observed in their study by Chougule SR (7). Here in this study, 6.2 % cases of septic arthritis were detected, which is almost similar to the observation (7%) made in previous study (11), though frequency was slightly more in the study by Dahiphale et al, where it was seen in 10% (4). Perthe's disease were seen only in 1.5 % case in this study. Almost similar percentage was reported by Ram et al where they observed it in 1.25 % cases (13). Higher frequency was reported by many of the earlier studies ranging from 4% to 8% (2, 4 - 6).

Total 9.23 % cases of neoplastic diseases were detected in this study. Slightly higher frequency was observed in some previous studied (7, 13). Pathology of this category were 13.97 % as seen by Chougule SR (7). Ram et al observed neoplastic pathology in 12.5 % cases (13). But lower percentage was reported by Chhabra et al (14) and Vaghamashi et al (15), who observed in 4% & 3.84 % respectively. In present study, Osteoid osteoma was in 1.5 % cases. This type of lesion were detected in 2.5 % & 4% cases by Ram et al (13) & Dahiphale et al (4) respectively, which is not far away from this study. Total two cases (3.1 %) of giant cell tumor were seen in this study. This is comparable to the study by Ram et al where they had seen it in 2.5 % cases (13). Metastatic lesion in 3.1 % cases; various literature reveals that the frequency of same ranges from 1.6 % to 6.6 % (2, 5, 6).

## CONCLUSION

Magnetic resonance imaging (MRI) is the optimal approach for identifying hip pathologies due to its high resolution, improved tissue contrast differentiation, and multiplanar imaging capabilities. It can accurately demonstrate abnormality of articular cartilage, hip joint effusions, subchondral bone, ligaments, muscles and juxta articular soft tissues. This is the modality of choice in characterizing the various disorders and assessing their extent of osseous, chondral and soft tissue component. MRI can stage the pathology to prognosticate and influence therapeutic decisions.

## REFERANCES

1. Takatori Y, Kokubo T, Ninomiya S, et al. 1993. Avascular necrosis of the femoral head. Natural history and magnetic resonance imaging. *J Bone Joint Surg Br.*, 75(2):217-21.
2. Tripathi P, Singh S, Khantal N. 2016. Hip Pathology Findings on Magnetic Resonance Imaging: A Study from Tertiary Care Institute. *Int J Sci Stud.*, 4(3):35-38.

3. RamBhamu S, Kardam N, Gehlot K, Khan A. 2017. The Role of MRI in The Evaluation of Painful Hip Joint. *IRPMS*. 3(2):1-12.
4. Dahiphale AP, Lule A, Rote V, Bhandari P. 2020. Magnetic resonance imaging in evaluation of hip joint pathologies. *Med Pulse International Journal of Radiology*. March 13(3): 168-171.
5. Vinay NVP, Sudha K J, Vineela LM, Chandra T J. 2020. A study to find the utility of MRI in the evaluation of painful hip joints. *Int J Med Res Rev.*, 8(4):315-319.
6. Narra RK, Kolipe SP, Bhimeswara Rao P, et al. 2018. Magnetic resonance imaging in evaluation of painful hip joint. *J. Evid. Based Med. Healthc.*, 5(50), 3406-3412.
7. Chougule SR. 2022. The role of magnetic resonance imaging in non-traumatic chronic hip joint pain in adult rural population. *Int J Res Med Sci.*, 10:2821-5.
8. Mahadevan V, Sapthagirivasan V. 2010. Information processing of medical images for the detection of osteoporosis in hip region of interest. *Int J Innov Management Technol*. 1(5):516.
9. Kalekar T, Shriramwar P. 2017. Role of magnetic resonance imaging findings in evaluation of painful hip joint. *International Journal of Medical and Health Research.*, 3(7):105-111.
10. Reddy KV, Kapoor A. 2017. MR Evaluation of Non-Traumatic Hip Pain. *JMSCR*. 05(03):19090-101.
11. Drar HAEAE. The Role of MRI in the Evaluation of Painful Hip Joint (MRI of Hip Joint). *Int J Med Imaging*, 2014; 2(3):77–82.
12. Shourbagy K, Ghith L, Hablas L. 2022. Magnetic resonance imaging (MRI) in diagnosis of non-traumatic hip joint pain. *Int J Radiol Diagn Imaging.*, 5(3):11-17.
13. Ram H, Kumar R, Vashisht A, et al., 2018. HIP pathology findings on magnetic resonance imaging-a prospective study. *J.Evid.BasedMed.Healthc.*, 5(42), 2938-2943.
14. Chhabra S, Kaur N, Bhatnagar S, Chhabra P, Puri S. 2020. MRI Evaluation of Painful Hip Joint. *Asian J. Med. Radiol. Res.*, 8(1):122-127.
15. Vaghamashi A, Bhatt J, Doshi J, Patel V. 2017. MRI in Evaluation of painful Hip Joint. *J Appl Dent.*, 16(5):85–96.

\*\*\*\*\*