



ISSN: 0975-833X

RESEARCH ARTICLE

MORPHOLOGICAL STUDY OF TRACHEO-BRONCHIAL TREE AND LUNGS OF HEDGEHOG
(*HEMIECHINUS AURITUS*)

*Ammar Ismail Jabbar and Rabbab abdl Al ammer

Department of Anatomy and Histology, College of Vet. Med., Diyala University, Iraq

ARTICLE INFO

Article History:

Received 16th December, 2013
Received in revised form
20th January, 2014
Accepted 19th February, 2014
Published online 25th March, 2014

Key words:

Morphology,
Morphometric,
Lung, trachea,
Bronchial tree,
Hedgehog.

ABSTRACT

This study was carried out on eight healthy adult of local hedgehogs of both sex, to elucidate the normal morphology and architecture in the conducting region of respiratory system of hedgehog and distinguish the normal lobulation of lungs. The animals were divided in to two groups. Groups –A for anatomical study, while group -B fore cast technique. The mean length, diameters of both trachea and bronchi also the number of lung lobes are recorded. The trachea was observed to be cartilaginous tube extend from larynx to the lung at thorax terminates by bifurcating in to the right and left principle bronchi above the base of the heart at the 4th thoracic vertebra. The right primary bronchus branched into three secondary lobar bronchi which provide each lobe of right lung (cranial, caudal, middle) while the bronchus of the accessory lobe arise from the middle secondary bronchi. The left primary bronchus is branched directly into several tertiary bronchioles. The lungs were observed to be sponge organ pink color, occupied most of the thoracic cavity, consisting of five portions. The right lung has four lobes cranial middle, caudal and accessory lobes. The caudal lobe is largest one, while the smallest one is the accessory lobe. The left lung has only one lobe occupied most the left side of thoracic cavity.

Copyright © 2014 Ammar Ismail Jabbar and Rabbab abdl Al ammer. This is an open access article distributed under the Creative Commons Attribution License, which permits unrestricted use, distribution, and reproduction in any medium, provided the original work is properly cited.

INTRODUCTION

Hedgehogs belong to the family Erinaceidae, order Insectivora (Corbet 1988). The (native species) Iraqi hedgehog is under the long ear hedgehog *Hemiechinus auritus* (Hutterer 2005) Fig (1). The respiratory system is essential for gaseous exchange between air and blood the lower respiratory system is consist of trachea, two bronchi, bronchioles and two lungs. Trachea: was flexible mathematical model tube extended from cricoids cartilage of the larynx to the tracheal bifurcation within thorax. It is kept permanently open by a series of in complete cartilaginous rings embedded in its wall. (Konig and Liebich 2009) The number of the tracheal cartilages varies among mammals. Lung: The right and left lungs occupy much the greater part of the thoracic cavity. It is soft, spongy texture, highly elastic air filled organs. In most animals the lungs are divided into well defined regions called lobes. These lobes are distinguished by the major branches of the bronchi, rather than by the external visible grooves and cleft. The pattern of lung lobes is fairly consistent among the common domestic species (Thomas and Joanna 2008). Despite some macro-anatomical investigations on the respiratory systems of cat (Mirhish and Nasser 2013), guinea pig (Schneider and Hutchens 1980). Rat, (Nakakuki 1983; Lee *et al.*, 2008; Legaspi 2010) Mice (Dimitrov *et al.*, 2005), Hamster (Kennedy *et al.*, 1978), But

the literature on the macro-anatomical features of the Respiratory system in hedgehogs is meager. The aim from this study to know an information about architecture in the conducting region of respiratory system of hedgehog and distinguish the normal lobulation of lung.

MATERIALS AND METHODS

Eight healthy adult of local hedgehogs of both sex, were collected from fields and divided into two groups. Groups –A for anatomical study, while group -B fore cast technique. The animals were weight before anesthetized intra muscular ketamin zylazin (15mg/ kg body weight). Group A for anatomical study, after scarifying of the animals the skinning of ventral surface of neck and thorax was done, then thoracic cavity opened. The trachea and lung were exposed to study the general description, and removal the lung and trachea from thoracic cavity for measuring, weight, length, diameter, and enumerate the tracheal rings and lung lobes. Cast technique is used to describe the course and measurements of trachea and principle bronchi and terminations, also lung lobulation. After scarifying animals and the trachea and lung become exposed a suitable plastic cannula insert through larynx and injected the resin (Acrylic cold) into trachea. After injection the cold acrylic (resin) left the specimens at room temperature for 24 hours before maceration used concentrated HCL. Each specimen was putting in suitable plastic jar, and late washed by tap water (Tompasett 1970; Phalen *et al.*, 1973 a). The

*Corresponding author: Ammar Ismail Jabbar, Department of Anatomy and Histology, College of Vet. Med., Diyala University, Iraq.

parameters were measured with the help of electrical digital vernier. All data were analyzed using SPSS version 17 (SPSS Inc., Chicago, IL, USA) for Windows. One sample T-test analysis was used. The results are expressed as means \pm SEM. The results were regarded as significant when $P < 0.05$.

RESULTS AND DISCUSSION

The conducting air ways of respiratory system in hedgehog consist of trachea bronchial tree and two lungs. The trachea is a flexible cartilaginous cylindrical tube extends from the caudal border of ring shape cricoid cartilage of the larynx at the level of atlanto-occipital through the ventral aspect of the neck in to the lung at thorax. It terminates by bifurcating in to the right and left principle bronchi above the base of the heart at the 4th thoracic vertebra Fig (2, 3). The total length of trachea about (29.7 ± 0.40 mm) Table (1), topographically divided into two part, the cervical part (19.9 ± 0.50 mm) runs from the larynx to the thoracic inlet, while the thoracic part (8.96 ± 0.26 mm) continuous to the bifurcation Table (1), this result is in agree with the result of (Dimitrov *et al.*, 2005). The tracheal rings about (23.2 ± 0.58) Table (1) cartilaginous c-shape ring. This result corresponding with the number of tracheal rings is similar to the result of (Ibe *et al.*, 2011) in african giant rat, (Kennedy *et al.*, 1978) in golden hamster, and disagree with result of (Al-anbki and Atya 2013) who mentioned that the number of tracheal ring in the rabbit about (45-47). This difference in numbers of tracheal ring may be due to the different in activity of the animal also, the hedgehog is consider as a nocturnal habit this led to has a little ventilation.

The tracheal ring has oval shape in cross section Fig (5) Their lateral- lateral diameter is (3.67 ± 0.077 mm) and the dorso – ventral diameter is (2.24 ± 0.14 mm) Table (1). This result agrees with the result of (15) in the rabbit, (9) in Rat, but disagree from that in hamster (10) and in cat (5), which is present as a semicircular. The lung of local hedgehog is sponge organ pink color, occupied most of the thoracic cavity from 3rd to 8th rib. The lung consists of two portion right and left lung. The right lung extended from 3rd rib to the 8th rib. It is divided anatomically by fissures into four lobes cranial (apical), middle (intermediate), caudal (diaphragmatic) and accessory lobes. The caudal lobe is largest one, while the smallest one is the accessory lobe Fig (3, 4). This result coincide with most researches studies on most domestic animals have four lobes (16, 8, 14, 15, 5). The left lung has only one lobe occupied most the left side of thoracic cavity with the heart extended from 3rd to the intercostals space between 8th and 9th rib, Theses observations are similar to that in giant pouched Rat (14), and giant Rat (7) and different from other rodents like the guinea pig which has lung with seven lobes (6) and Logomorpha represented by local Iraqi rabbit has lung with six lobe four in right and two in left lung (Al-anbki and Atya 2013; Ramchandi *et al.*, 2001) in rabbit. The left lung has small size when compared with right lung due to the presence of heart near left lung Fig (3).

A resin (cold acrylic) airway technique performed in freshly killed animal to provide three dimensional cast pattern of Tracheo-bronchial and its terminal bronchioles, also the lobulation of hedgehog lung. The diameter of right bronchus

(1.85 ± 0.30 mm) is larger than left bronchus (1.57 ± 0.71 mm) Table (1). This result is compatible with the result of (5) in the cat. This difference may be to increase the ventilation efficiency to the left bronchus which is supply four lobes. The right primary bronchus before entering the parenchyma of the right lung is branched into three secondary lobar bronchi which provide each lobe of right lung (cranial, caudal, middle) while the bronchus of the accessory lobe arise from the middle secondary bronchi. The left primary bronchus after entering the parenchyma of the left lung at hilus is branched directly into several tertiary bronchioles Fig. (4 and 5). This result agrees with the result of (7 and 14) in Rat.

Table 1. showing the parameters of Trachea in hedgehog

Number of tracheal ring	23.2 \pm 0.58
Total tracheal length	29.7 \pm 0.40 mm
Length of cervical part of trachea	19.9 \pm 0.50 mm
Length of thoracic part of trachea	8.96 \pm 0.26 mm
Diameter of trachea(latero-lateral)	3.67 \pm 0.077 mm
Diameter of trachea(dorso-ventral)	2.24 \pm 0.14 mm
Diameter of right principle bronchus	1.85 \pm 0.30 mm
Diameter of left principle bronchus	1.57 \pm 0.71 mm

Values represent mean \pm S.E (P 0.05)



Fig. 1. Photograph of mature long ear hedgehog before dissects.

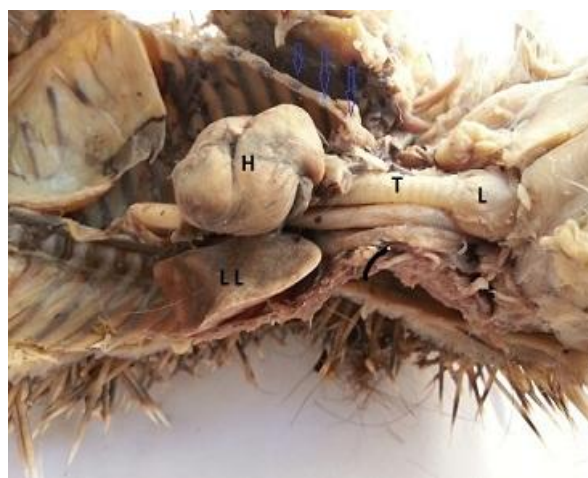

Fig. 2. Photograph illustrates anatomical position (ventral view):
l- larynx, T-trachea, H- heart, LL-left lung

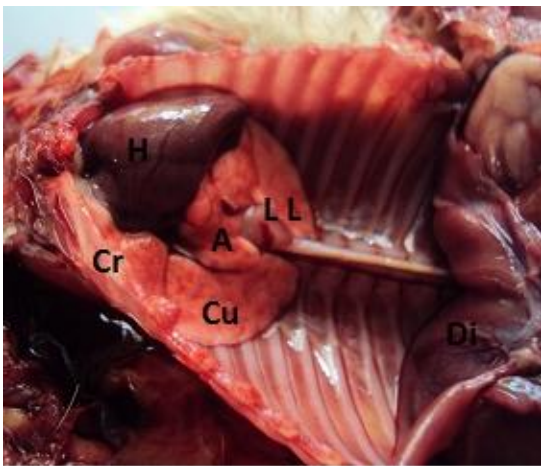


Fig. 3. Shows topographic location of lung and its division H- heart, Right lung: Cr-cranial lobe Cu-caudal lobe, A-accessory lobe, LL- left lobe

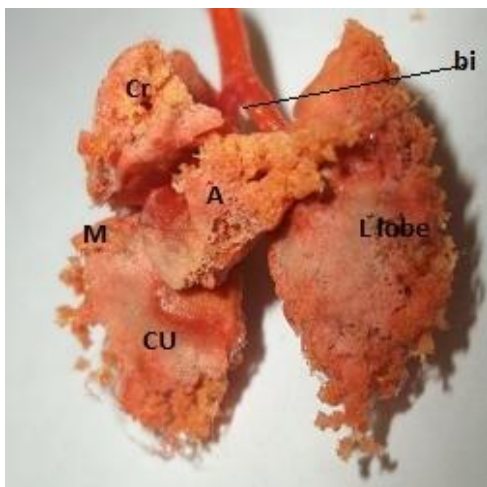


Fig. 4. show the ventral aspect of lungs cast and trachea of the hedgehog illustrates: bi-bifurcation, L-left lobe, Right lobe consist of Cr-cranial lobe, A- accessory lobe, M-middle lobe, Cu- caudal lobe

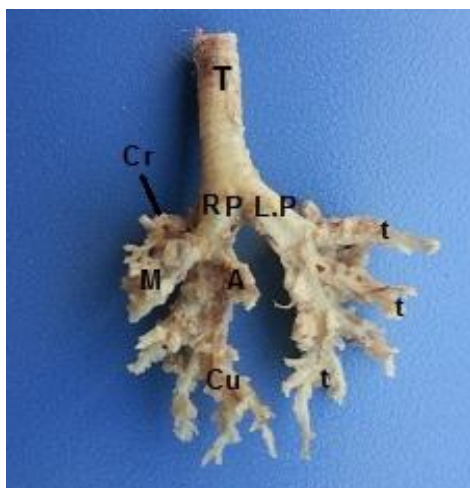


Fig. 5. Shows architecture or Tracheo- bronchial tree of lung hedgehog Rp-right principle bronchus, LP- left principle bronchus, secondary bronchus provide Cr-cranial lobe, M-middle lobe, A- accessory lobe, Cu-caudal lobe, t- tertiary bronchioles

REFERENCES

- Al-anbki, A.A. and Atya, M. A. 2013. Anatomical, Histological and radiological study of trachea and lung in domesticated local rabbits. M.Sc. Thesis submitted to Veterinary Medicine College, university of Baghdad.
- Corbet, G.B. The family Erinaceidae: a synthesis of its taxonomy, phylogeny, ecology and Zoogeography. *Mammal Rev.* 18 (3):117-172. 1988.
- Dimitrov, D., Dimitrova, G. Nikolova, G. Savov, S. 2005. Histological investigation of the glandular and respiratory epithelium in the mice trachea and lung after oral administration of Ambroxol. 3(5): 8-10.
- Hutterer, R. 2005. "Order Erinaceomorpha". In Wilson, D. E.; Reeder, D. M. *Mammal Species of the World* (3rd ed.). Johns Hopkins University Press. pp. 212-217. http://en.wikipedia.org/wiki/Long-eared_hedgehog#cite_ref-Qumsiyeh_3-6.
- Ibe, C. S., salami, S.O. and Onyeanus, B. I. 2011. Macroscopic anatomy of the lower respiratory system nocturnal burrowing rodent African ginat pouched rat *Cricetomys gambianus*, water house 1840) *Anat. Histo. Embryo.* 40: 112-113.
- Kennedy, A. R., Desrosiers, A., Trazaghi, M. and Little, J.B 1978. Morphometric and Histological analysis of the lungs of Syrian golden hamster. *J. Anat.* 125(3):527-553.
- Konig, H.E. and Liebich, H.G. 2009. *Veterinary Anatomy of Domestic Mammals Textbook and Color Atlas 4th ed.* Schatteuer.
- Lee, D., Park, S.S., Weiss-Ban, G.A. Fanucchi, M.V., Plopper C.G and Wexler, A.S. 2008. Bifurcation model for characterization of pulmonary architecture. *Anat. Rec.* 291:379-389.
- Legaspi, M. S. 2010. Comparative safety respiratory pharmacology: Validation of head out plethysmography pneumotachometer testing device in mole Sprague. Dawley rats beagle dog and cynomolgus monkeys. M.Sc. Thesis university de montreal. pp:6-14.
- Mirhish, S.M. and Nasser, R. A.: 2013. Anatomical and histological study of trachea and lung in local breed cats *felis Catus domesticus* 3(2) :266-272.
- Nakakuki, S. (1983): The bronchial tree and blood vessels of the rat lung. *Ana. Anz.* 154:305-318.
- Phalen, R.F., Yen, H. c. Raabe, O. G. and Velasquez, D.J.1973. a) Casting the lung in situ. *Ana. Rec.*, 177: 255-263.
- Ramchandi, R., Bates, J. H., Shen, X., Suki, B. and Tepper, R.S. 2001. Air way branching morphology of mature and immature rabbit lungs. *J. Appl. Physiol.*, 90:1584-1592.
- Schreider, p.J. and Hutchens, O.J.1980. Morphology of the guinea pig respiratory tract. *Anat. Rec.*,196: 313-321.
- Thomas, C. and Joanna, M. B. 2008. *Clinical anatomy and physiology for veterinary technician 2nd Ed.* Mosby Elsevier.
- Tompasett, D.H. 1970. *Anatomical technique 2nd ed.* Longman group limited. London great pritian.
- Valerius, K., 1996. Size- dependent morphology of the conductive bronchial tree in four species of myomorph rodents. J. Morphometry of peripheral air way system in rat and rabbit. *Am. J. Anat.* 180: 143-155.
