



RESEARCH ARTICLE

A RARE ANATOMICAL ASPECT: THE APPENDICEAL PREGNANCY

*Manyacka Ma Nyemb, P., Ehode, C., Badiane, S. M., Diao, M. L., Tendeng, J. N. and Ndaw, A. L.

Department of General Surgery, Regional Hospital of Saint-Louis, BP 234, Saint-Louis, Sénégal

ARTICLE INFO

Article History:

Received 15th February, 2014
Received in revised form
04th March, 2014
Accepted 10th April, 2014
Published online 20th May, 2014

Key words:

appendiceal pregnancy,
gangrenous appendicitis,
abdominopelvic
ultrasonography.

ABSTRACT

Appendiceal pregnancy is a rare form of abdominal pregnancies. The occurrence of this type of pregnancy is under the influence of risk factors of ectopic pregnancies such as sequelae of genital infections, a low socio-economic level and inadequate medical care. The authors report the case of a patient of Saint-Louis in Senegal, aged of 36, who presented an appendiceal pregnancy simultaneously with a gangrenous appendicitis. The appendiceal location of abdominal pregnancy is exceptional in our context. If clinical examination is sometimes inconclusive, the abdominopelvic ultrasonography confirms the diagnosis as in most of ectopic pregnancies. The treatment of choice is surgical.

Copyright © 2014 Manyacka Ma Nyemb et al. This is an open access article distributed under the Creative Commons Attribution License, which permits unrestricted use, distribution, and reproduction in any medium, provided the original work is properly cited.

INTRODUCTION

The appendiceal pregnancy is one of the exceptional forms of abdominal pregnancies. Abdominal pregnancy is defined as implantation and development of the fertilized ovule into the peritoneal cavity. It is a variant of ectopic pregnancies and the appanage of countries with low socio-economic status and low medical care (Mahi *et al.*, 2002). In our context, abdominal pregnancy is a rare event and represent 1% of ectopic pregnancies and about 0, 02% of deliveries (Rabbarijaona *et al.*, 2000). We report a rare anatomical form of abdominal pregnancy attached to the vermiform appendix and pediculated to the mesoappendix. This is a case was managed at the Regional Hospital of Saint-Louis.

Observation

Mrs. M.A.D. is a housewife aged of 36, four (4) pregnancies and four (4) children alive and well being. She was transported to the Emergency Ward because of abdominopelvic pain and bilious vomiting. She came from a low socio-economic level and lived in rural areas. It was found a notion of secondary infertility. Mrs. M.A.D. did not know she was pregnant, so no antenatal care had been made, nor any obstetric ultrasonography performed until then. No real amenorrhea was found when questioning M.A.D. Clinical examination revealed a poor general condition: mucocutaneous pallor, cachexia, and

asthenia. Blood pressure at admission was 80 /50 mm Hg, heart rate 95 beats / minute and temperature 37.4 ° C. Mrs. M. A. D. weighed 53 kg for 169 cm. Abdominal examination revealed a swelling of the right iliac fossa overflowing on the right flank, the periumbilical region and hypogastrium (Figure 1). Uterine size was difficult to measure. Palpation found a significant mass fixed in the right iliac fossa. The genital exam found a closed and posterior short cervix, with a sensitive pouch of Douglas, the uterus was difficult to define. Inflammatory profile and pregnancy test were positive. The hemogram showed normocytic normochromic severe anemia with a hemoglobin of 3.9 g / dl. Obstetric ultrasonography highlighted an empty uterus and a non-evolutive pregnancy in the abdominal cavity. The fetal biometry corresponded to 16 weeks of gestation. Because of these clinical features, a vascular filling was performed. The patient also received several blood transfusions. A monitoring was done clinically, biologically and by ultrasonography. Following the increasing of hemoglobin and to the worsening of abdominal pain syndrome, a laparotomy was indicated and urgently performed. The operatory findings were an encysted abdominal pregnancy located in the right iliac fossa, and an important left hydrosalpinx. The pregnancy presented multiple adhesions with the vermiform appendix, the greater omentum, the small bowel, the mesentery and the Douglas pouch (Figures 2, 3 and 4). The abdominal pregnancy was pediculated to the appendix, and it contained the distal 2/3 of the appendix. The pregnancy was carefully released from its adhesions, and extracted once (Figure 5). Appendicectomy and left salpingectomy were performed. At the opening of the mass, we found a macerated

*Corresponding author: Manyacka Ma Nyemb

Department of General Surgery, Regional Hospital of Saint-Louis, BP 234, Saint-Louis, Sénégal.

fetus weighing 150 grams and surrounded by its placenta (Figure 6). The pathological examination of the mass showed a non-viable encysted pregnancy in an advanced state of maceration, and a gangrenous appendix perforated at its distal end. The postoperative course was uneventful and the patient was discharged on the 7th postoperative day with progestin contraception. After a year of monitoring, no pathological marking fact was discovered.

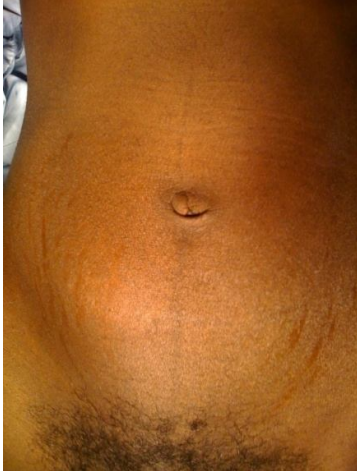

Figure 1. Abdominal swelling on the right iliac fossa

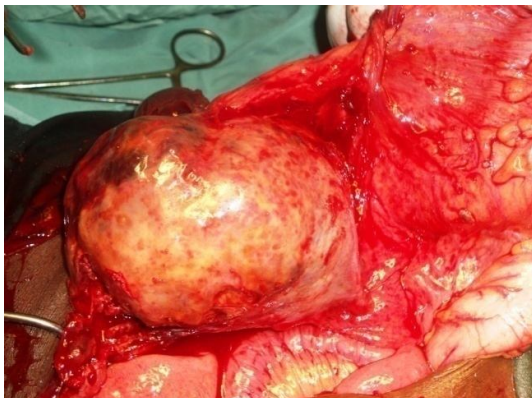


Figure 2. Exposure of the mass and its mesenteric adhesions

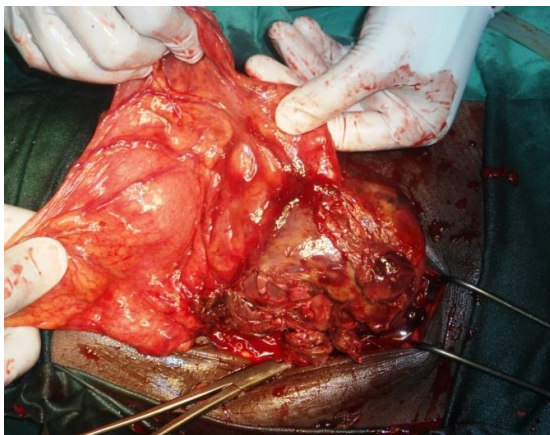


Figure 3. Exposure of the mass and its adhesions with the small bowel and the mesentery

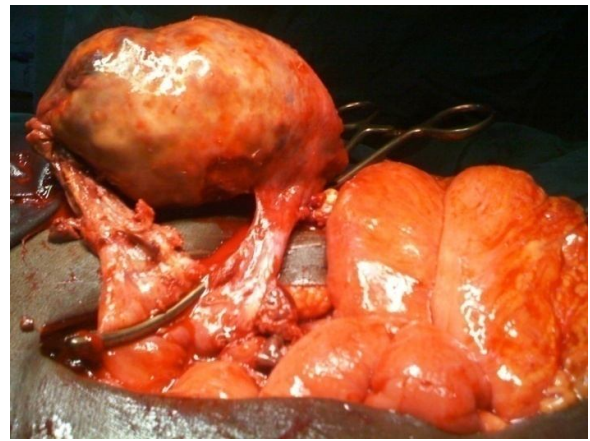

Figure 4. Exposure of the mass and its adhesions with the appendix and mesoappendix

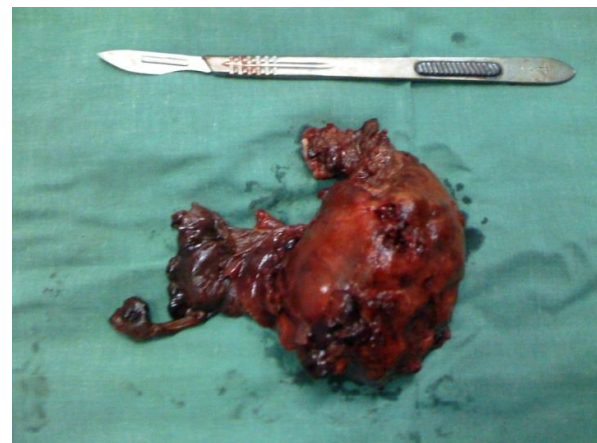


Figure 5. Presentation of the mass after ablation

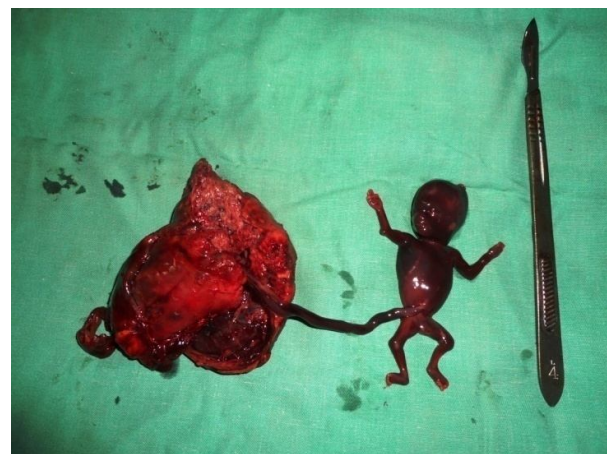

Figure 6. Showing of the mass content after opening

DISCUSSION

The description of ectopic pregnancies dates back to the 10th century when Albucasis, spanish physician, described a patient discharging fetal parts through the abdominal wall in the

umbilical region (described further as an umbilical fistulae) (King, 1954), (Ben *et al.*, 1995). Since that time, it was found that abdominal pregnancies may have many clinical features, and can attach to most of intra-abdominal organs. The rarest sites include the mesentery, omentum, the bladder wall, the appendix and the liver (Ben *et al.*, 1995), (Jeffcoate, 1975). Reasons of that anatomical variability are poorly understood. The frequency of abdominal pregnancy is influenced by risk factors for ectopic pregnancies, such as sequelae of genital infections and a low socio-economic level (Guèye *et al.*, 2012), (Mahi *et al.*, 2002). In developing countries, the incidence of abdominal pregnancies is increased by two factors: the incidence of genital infection and inadequate monitoring of pregnancy (Rabbarijaona *et al.*, 2000). These two factors were found in the case of our patient. In the literature, abdominal pregnancies were sometimes associated with splenomegaly, bowel obstruction, or urogenital tuberculosis with hemolytic anemia (Partington *et al.*, 1986). Association of appendicitis with a pregnancy is possible in a small proportion of cases. In a series of 42936 deliveries, Brant (1967) found 24 cases of appendicitis histologically proven, that is to say 0.06 %. In the case of ectopic pregnancies, the occurrence of appendicitis is exceptional (Bang Ntamack *et al.*, 2012). The concomitant occurrence of these two conditions has been reported in only few cases (Thompson *et al.*, 2011), (Hazebroek *et al.*, 2007). It has been shown that during pregnancy, the right fallopian tube can cause an inflammatory response of the appendix, and then secondary peri-appendicitis (Pelosi *et al.*, 1979). In our patient, the right fallopian tube was macroscopically healthy. The direct implantation of an ectopic pregnancy on the appendix is extremely rare, with less than 5 cases identified in the literature (Nama *et al.*, 2007). The fact that our patient was initially admitted to the internal medicine department reflects the degree of confusion created by this atypical presentation. Physical examination found a significant and non-specific swelling in the right iliac fossa. Genital examination was poor. Given the difficulty of clinical diagnosis, abdominal ultrasonography plays an important role. In the case of our patient, ultrasonography was decisive. It helped to highlight an empty uterus and a non-evolutive pregnancy located in the right iliac fossa. The treatment of choice for abdominal pregnancies is surgical. Our patient underwent conventional laparotomy. However, laparoscopic surgery is a diagnostic and therapeutic method. It should be preferred when the history and symptoms of the patient allow it (Seol *et al.*, 2010).

Conclusion

Appendiceal pregnancy is exceptional in our context. Clinical examination and abdominopelvic ultrasonography are very important in early diagnosis. The treatment of choice is surgical.

REFERENCES

- Bang Ntamack JA, Ngou Mve Ngou JP, Sima Ole B, Sima Zue A, Mayi Tsonga S *et al.* 2012. Grossesse abdominale à Libreville de 1999 à 2009. *Journal de Gynécologie Obstétrique et Biologie de la Reproduction*, 41(1):83-87.
- Ben RZ, Dekel A, Lerner A, Orvieto R, Halpern M, Powsner E, Voliovitch I. 1995. Laparoscopic removal of an abdominal pregnancy adherent to the appendix after ovulation induction with human menopausal gonadotrophin. *Hum Reprod*, 10:1804-1805.
- Brant HA. 1967. Acute appendicitis in pregnancy. *Obstet Gynecol*, 29 :130-138.
- Guèye M, Cissé ML, Guèye SMK, Diaw H *et al.* 2012. Difficulté du diagnostic et de prise en charge de la grossesse abdominale: à propos de deux cas diagnostiqués à terme au Centre Hospitalier Régional de Diourbel du Sénégal. *Clinics in Mother and Child Health*, 9:3p.
- Hazebroek EJ, Boonstra O, van der Harst E. 2008. Concurrent tubal ectopic pregnancy and acute appendicitis. *J Minim Invasive Gynecol*, 15(1):97-98. doi:10.1016/j.jmig.2007.06.009
- Jeffcoate N. 1975. Ectopic pregnancy. In Jeffcoate N, ed. *Principles of Gynaecology*. New York, Edinburgh and London: Butterworths: 207-19.
- King G. 1954. Advanced intrauterine pregnancy. *Am J Obstet Gynecol*, 161:712-740.
- Mahi M, Boumdin H, Chaouir S, Salaheddine T, Attioui D *et al.* 2002. Un nouveau cas de grossesse abdominale. *J Radiol*, 83 :989-992.
- Nama V, Gyampoh B, Karoshi M, McRae R, Opemuyi I. 2007. Secondary abdominal appendicular ectopic pregnancy. *J Minim Invasive Gynecol*, 14(4):516-517. doi:10.1016/j.jmig.2007.02.005
- Partington CK, Studley JGN, Menzies-Gow N. 1986. Abdominal pregnancy complicated by appendicitis: case report. *British Journal of Obstetrics and Gynaecology*, 93:1011-1012.
- Pelosi MA, Apuzzio J, Iffy L. 1979. Ectopic pregnancy as an etiologic agent in appendicitis. *Obstet Gynecol*, 53(3):4S-6S
- Rabbarijaona HZ, Rarakotovao JP, Rakotorahalahy MJM, Randriamlarana JM. 2000. La grossesse abdominale. *Med Afr Noire*, 47:460-463.
- Seol HJ, Kim T, Lee SK. Successful laparoscopic management of primary omental pregnancy. *Arch Gynecol Obstet* 2010; 218:163-135.
- Thompson RJ, Hawe MJG. A rare pathological trinity: an appendiceal ectopic pregnancy, acute appendicitis and a carcinoid tumour. *Ir J Med Sci* 2011; 180:579-580.
- Zaki ZMS. An unusual presentation of ectopic pregnancy. *Ultrasound Obstet Gynecol* 1998; 11(6):456-458.
