



ISSN: 0975-833X

RESEARCH ARTICLE

MORPHOMETRICAL CHARACTERISTICS OF TUMOR CELLS ARE PROGNOSTIC DETERMINANTS FOR ORAL SQUAMOUS CELL CARCINOMAS

¹Dr. Mahima Rakheja, ²Dr. Arunima Chauhan, ³Dr. Vasudeva Guddattu and
^{1,*}Dr. Monica Charlotte Solomon

¹Department of Oral Pathology, Manipal College of Dental Sciences, Manipal, Manipal University, Karnataka, India

²Faculty, Melaka Manipal Dental College, Manipal University, Karnataka, India

³Department of Biostatistics, Manipal University, Karnataka, India

ARTICLE INFO

Article History:

Received 22nd August, 2014

Received in revised form

20th September, 2014

Accepted 14th October, 2014

Published online 18th November, 2014

Key words:

Cell area,
Nuclear area,
Morphometry,
Prognosis,
Oral cancer,
Nuclear: cytoplasmic ratio.

ABSTRACT

Background: Oral Squamous Cell Carcinoma (OSCC) holds poor prognosis, mainly due to its delayed detection. Computer aided image analysis can serve as a useful adjunct to routine histological diagnosis for early diagnosis and efficient treatment planning.

Aim: To quantitate the nuclear and cellular morphological features in advancing grades OSCC to establish a reliable adjunct for diagnostic and prognostic purposes.

Material and Methods: 105 OSCC tissue sections, graded according to WHO grading system as well differentiated OSCCs (n=35), moderately differentiated OSCCs (n=35), poorly differentiated OSCCs (n=35) selected. 6 morphometrical parameters assessed using "image J 1.34 software", Namely the Nuclear Area (NA), Cell Area (CA), Nuclear to Cell Area Ratio (NA/CA), nuclear perimeter (NP), Cell Perimeter (CP) and nuclear to cell perimeter ratio (NP/CP). The data was statistically analysed.

Results: Nuclear area, cell area, nuclear perimeter and cell perimeter showed statistically significant alterations. Follow up analysis revealed nuclear area and cell area to be higher in the recurrent cases than the non recurrent ones

Conclusion: Nuclear and cellular features show significant alterations in tumor cells during the advancement of OSCC which hold diagnostic and prognostic importance.

Copyright © 2014 Dr. Mahima Rakheja et al. This is an open access article distributed under the Creative Commons Attribution License, which permits unrestricted use, distribution, and reproduction in any medium, provided the original work is properly cited.

INTRODUCTION

Accounting for 90% of all the oral malignancies, oral squamous cell carcinoma (OSCC) has been established as the most common type of malignancy of the oral cavity. In spite of considerable advances in the treatment modalities, the 5 year survival rate of OSCC is about 55% and it continues to stand poor. This is mainly attributed to the detection of the disease at a stage where its progress is difficult to control. The delay in detection of the disease can lead to ominous consequences. Unambiguously, early detection of oral OSCC is imperative in bringing down the high morbidity and mortality rate associated with it (Pich *et al.*, 2004). This can be a daunting task as OSCCs are tumors which boast dissimilar behavioural patterns. However, the assessment can be simplified by focussing on the elements that constitute as well as display major variations in OSCC, such as the malignant epithelial cells (Patel *et al.*, 2011), (Kulasekara *et al.*, 2009), (Remmerbach *et al.*, 2009). Regarding the cellular changes, considerable disparity has been

noticed among pathologists in terms of subjective evaluation of histopathological features of OSCC. To resolve this, computer-assisted morphometry can be used for reliable quantification of cellular and nuclear changes (Pindborg *et al.*, 1985), (Abbey *et al.*, 1985), (Karabulut *et al.*, 1985) (Brothwell *et al.*, 2003). Assessing these crucial changes displayed by the epithelial cells can help in more efficient diagnosis and management of the disease, along with a more accurate assessment of the patient prognosis.

There are a good number of studies which have employed morphometry for grading carcinomas of breast, kidney, prostate, colon and oesophagus and to distinguish oral hyperplasias and dysplasias, (Abdel-Salam *et al.*, 1987), (Baak *et al.*, 2002) oral lichen planus and lichenoid lesions (Khoo *et al.*, 2001). In this study we attempt to quantitate a particular set of nuclear and cellular morphological features in the advancing phases of OSCC using computer-aided image analysis and associate them with a routine histopathological grading system (WHO Grading) to establish a reliable adjunct for diagnostic and prognostic purposes.

*Corresponding author: Dr. Monica Charlotte Solomon

Department of Oral Pathology, Manipal College of Dental Sciences, Manipal, Manipal University, Karnataka, India.

MATERIALS AND METHODS

Following the approval from the Institutional Ethics Committee (IEC 444/2013), 105 formalin fixed paraffin embedded tissue blocks were retrieved from the departmental archives which consisted of 35 cases each of well, moderate and poorly differentiated histopathologically diagnosed cases of oral squamous cell carcinomas. The cases had been graded according to WHO grading system. 5 cases of normal mucosa taken as controls. The clinic pathological and follow up details were retrieved from the medical records files of the patients.

Morphometrical analysis

Fresh sections of 5 μm thickness were cut using a soft tissue microtome from the formalin-fixed, paraffin-embedded tissue blocks of OSCC cases and normal mucosa. The sections obtained were stained with Harris's Hematoxylin and Eosin. The sections were then subjected to morphometrical analysis. Only clearly defined cells were measured. Morphometrical parameters considered were: Nuclear area (NA), Cell Area (CA) and Nuclear-Cellular Area Ratio (NP/CP), nuclear perimeter (NP), Cell Perimeter (CP) and nuclear-cellular perimeter ratio (NP/CP). The scale for morphometrical analysis was standardized using an eye piece graticule and a stage grid in 40X magnification. For each case, pictures of 3 fields were taken under 40X magnification. Ten clearly defined cells were analyzed from each field. Image analysis was done using – "Image J 1.34 software" (Natrajan *et al.*, 2010) available at website: <http://rsb.info.nih.gov/ji/>.

In order to assess the slides in image J, the images are captured onto the hard drive of the computer, following which they can be opened in NIH Image/Image J for evaluation, using the various tools provided in the panel. (Mukherjee *et al.*, 2012) (Khandelwal and Solomon, 2010) (Figure 1) For calibration the scale for morphometrical analysis was standardized using an eye piece graticule and a stage grid in 40X magnification and the scale was set as 1 pixel = 6.03 microns. The software compiles all the data into Microsoft Excel worksheets to give a summated set of results for a single slide.

Statistical analysis

Statistical analysis was carried out using the SPSS package (version 15.0). One- way ANOVA (Analysis of Variance) was used for comparing the parameters for multiple groups. Comparison of the mean nuclear and cellular area and diameter values between groups was made using multiple comparison test by Tukey-HSD procedure. The results were considered significant when P -value < 0.05 .

RESULTS

Nuclear area

The mean nuclear area of poorly differentiated OSCC was found to be $162.04\mu^2$. One Way ANOVA test showed the value of mean nuclear area to be statistically significant among the grades of OSCC (P value = .025). Comparison between the groups using Post-Hoc test with Tuckey HSD method showed the value of poorly differentiated OSCC to be significantly lower than well differentiated OSCC (p value = .05) and moderately differentiated OSCC (p value = .042) (Figure 2 Table 1).

Cell area

The mean cell area of poorly differentiated OSCC was found to be $414.72\mu^2$. One Way ANOVA test showed the value of mean cell area to be statistically significant among the grades of OSCC (P value $< .0001$). Comparison between the groups using Post-Hoc test with Tuckey HSD method showed the value of poorly differentiated OSCC to be significantly lower than well differentiated OSCC (p value $< .0001$) and moderately differentiated OSCC (p value $< .0001$) (Figure 2, Table 1).

Nuclear area to cytoplasmic area ratio (NA/CA)

The mean NA/CA was found to be statistically insignificant among the different grades of OSCC (p value = .473) (Figure 2, Table 1)

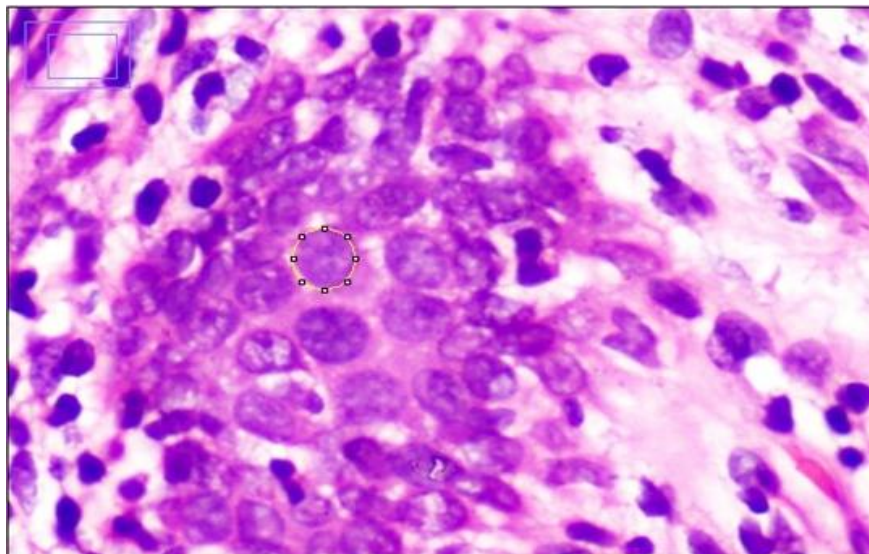


Figure 1. Nuclear parameters being measured in Image j software

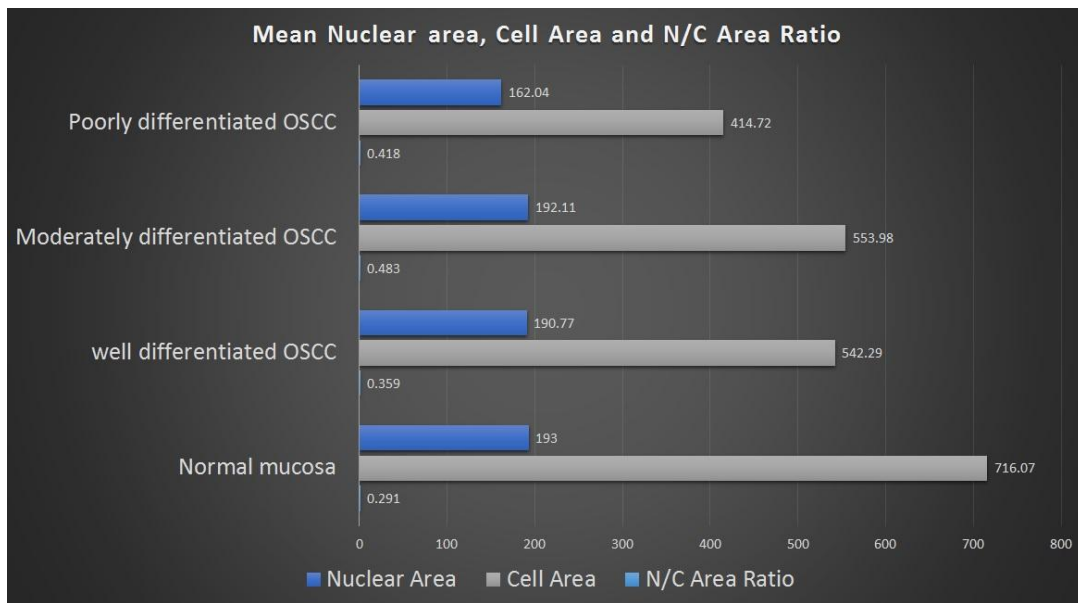


Figure 2. Figure showing nuclear area, cell area and N/C area in various grades of OSCC and normal mucosa (values in micron²)

Table 1. Statistical analysis using One – Way ANOVA test and multiple comparisons test (Post-Hoc test) with Tuckey HSD method (values in micron²)

Criteria	Grade of OSCC	Mean	Standard deviation	Confidence limit	P-value
Nuclear Area	Well differentiated (a)	190.77	54.48	172.05, 209.49	.025 Post hoc: ✓ (a) and (c)= .05 ✓ (b) and (c)= .042
	Moderately differentiated (b)	192.11	46.86	176.02, 208.21	
	Poorly differentiated (c)	162.04	52.57	1443.98, 180.10	
Cell Area	Well differentiated (a)	542.29	139.91	494.23, 590.35	<.0001 Post hoc: ✓ (a)and (c)= <.0001 ✓ (b)and (c)= <.0001
	Moderately differentiated (b)	553.98	127.48	510.19, 597.77	
	Poorly differentiated (c)	414.72	127.68	370.85, 458.58	
Nuclear/Cell Area	Well differentiated (a)	.359	.039	.345, .372	.473
	Moderately differentiated (b)	.483	.710	.239, .727	
	Poorly differentiated (c)	.418	.174	.358, .478	

Table 2. Statistical analysis using One – Way ANOVA test and multiple comparisons test (Post-Hoc test) with Tuckey HSD method (values in micron²)

Criteria	Grade of OSCC	Mean	Standard deviation	Confidence limit	P-value
Nuclear Perimeter	Well differentiated (a)	48.28	6.47	46.06, 50.51	.027 Post hoc: ✓ (b) and (c)= .03
	Moderately differentiated (b)	48.92	5.86	46.91, 50.94	
	Poorly differentiated (c)	44.88	7.49	42.30, 47.46	
Cell Perimeter	Well differentiated (a)	86.82	12.17	82.63, 91.00	<.0001 Post hoc: ✓ (a) and (c)= .001 ✓ (b) and (c)= <.0001
	Moderately differentiated (b)	88.88	9.95	85.46, 92.30	
	Poorly differentiated (c)	76.38	13.08	71.89, 80.88	
Nuclear/Cell Perimeter	Well differentiated (a)	.359	.039	.537, .575	.361
	Moderately differentiated (b)	.483	.710	.541, .574	
	Poorly differentiated (c)	.418	.174	-.687, 4.28	

Nuclear perimeter

The mean nuclear perimeter of poorly differentiated OSCC was $44.48\mu^2$ and One way ANOVA test showed it to be a statistically significant parameter (p value = .027). Comparison between the groups with post hoc test revealed its value in poorly differentiated OSCC to be significantly lower than well differentiated OSCC (p value = .03) (Figure 3, Table 2).

Cell perimeter

The mean cell area of poorly differentiated OSCC was found to be $76.38\mu^2$. One Way ANOVA test showed the value of mean cell area to be statistically significant among the grades of OSCC (P value < .0001). Comparison between the groups using Post-Hoc test with Tuckey HSD method showed the value of poorly differentiated OSCC to be significantly lower than well differentiated OSCC (p value = .001) and moderately differentiated OSCC (p value < .0001) (Figure 3, Table 2).

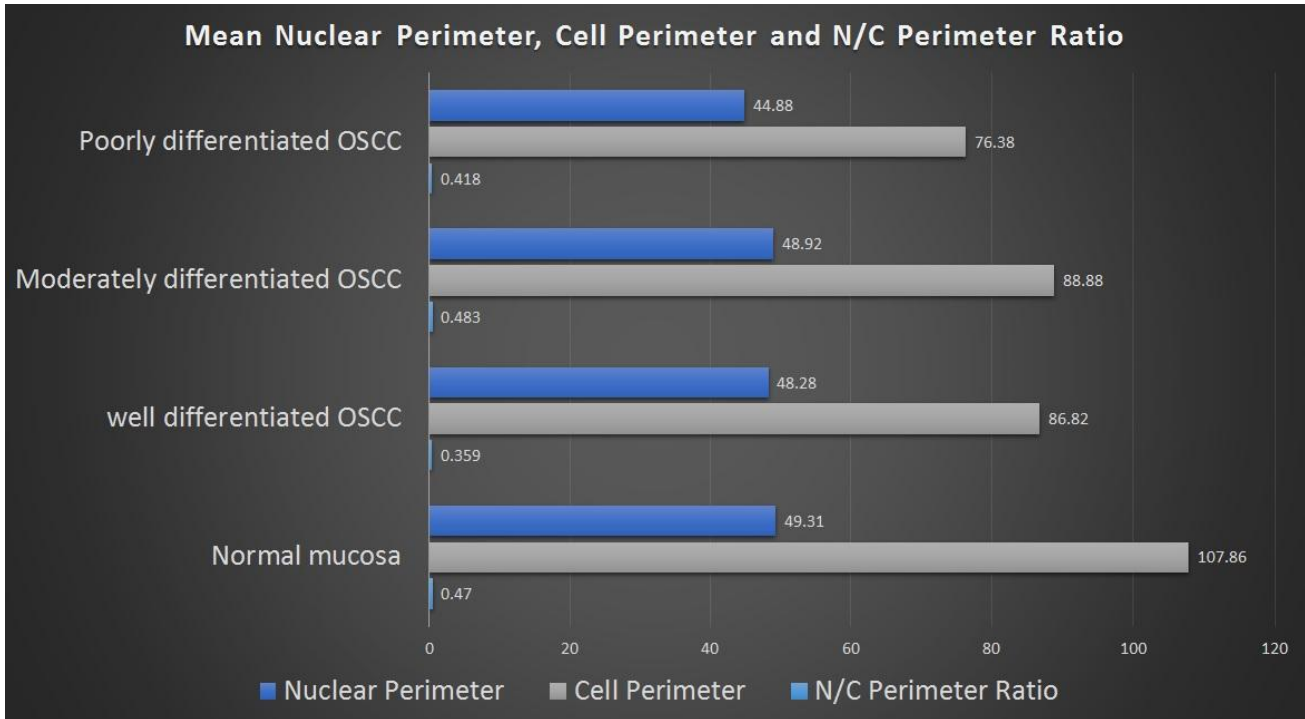


Fig. 3. Figure showing nuclear perimeter cell perimeter and N/C perimeter in various grades of OSCC and normal mucosa (values in micron²)

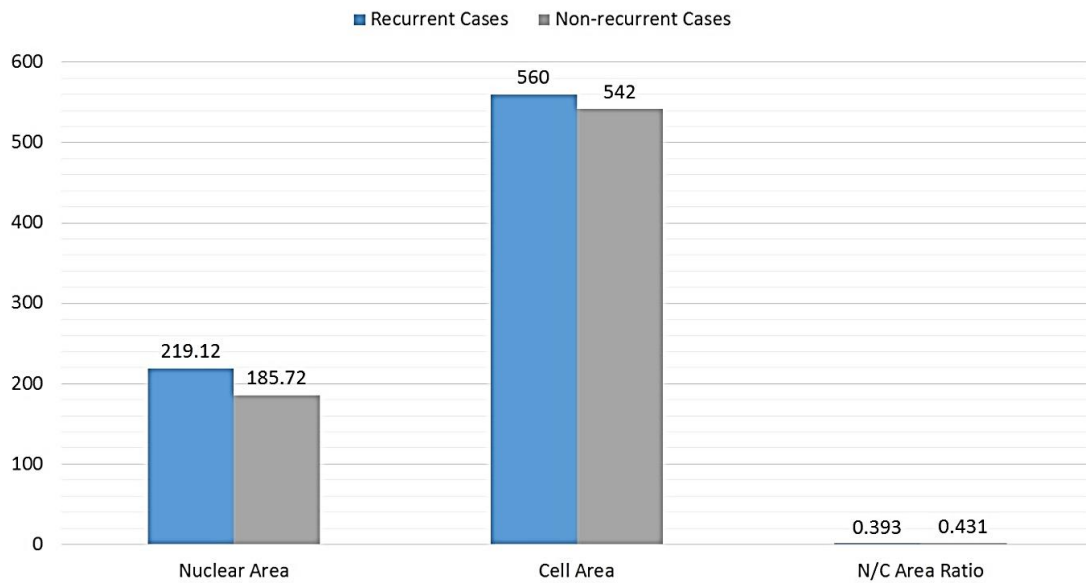


Fig. 4. Figure showing comparison between recurrent and non recurrent cases with respect to nuclear area, cell area and their ratio (values in micron²)

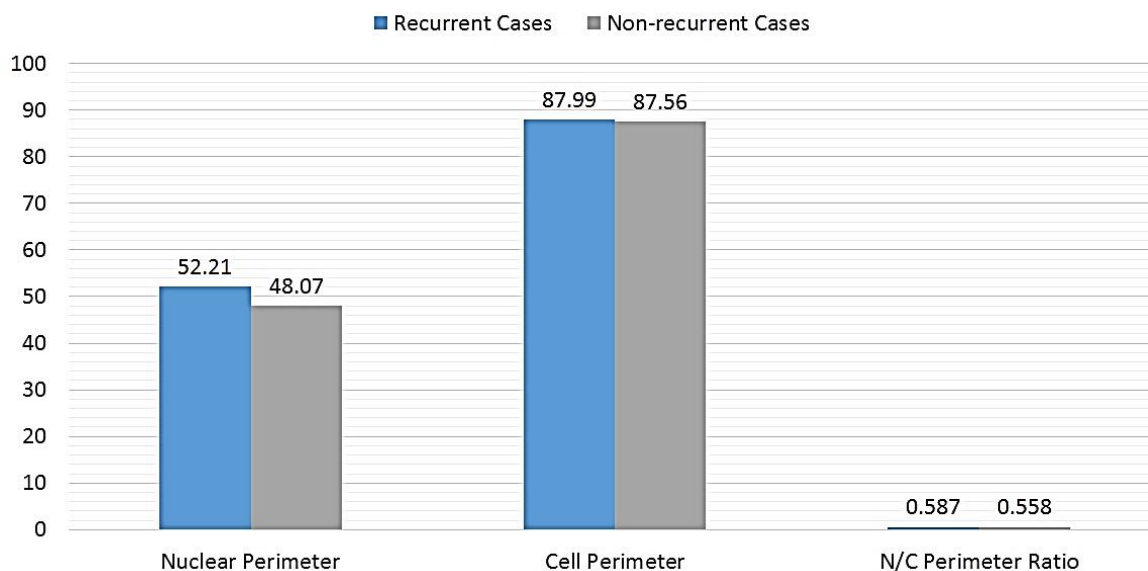


Fig. 5. Figure showing comparison between recurrent and non recurrent cases with respect to nuclear perimeter, cell perimeter and their ratio (values in micron²)

Nuclear perimeter to cytoplasmic perimeter ratio (NP/CP)

The mean NP/CP was found to be statistically insignificant among the different grades of OSCC (p value = .361) (Figure 3, Table 2)

Follow up and recurrence analysis

The cases were followed up for a period of 3 years and 5 months. Among the 105 cases, 62 were available for follow up, out of which 8 patients showed loco-regional recurrence (12.9%). After their morphometrical analysis it was seen that nuclear area, cell area and nuclear perimeter were higher in the recurrent cases as compared to the non recurrent ones. (Figure 4 and 5)

DISCUSSION

Oral squamous cell carcinoma (OSCC) is known for its stealth as it progresses and causes severe damage to the tissues involved. Normally, clinical staging and histological grading are used to evaluate OSCC which are more or less subjective and not efficiently reproducible. It is certain that it will take more than just routine histological methods to detect and halt this disease before its characteristic progression to serious impairment. Quantitative histo-morphometric techniques can detect certain important features that may be overlooked by routine H&E staining. Thus, when employed as an adjunct, these techniques can lead to improved and timely diagnosis as well as prognostication. Research and technology go hand in hand. Image analysis is one such segment of scientific technology which many researchers and practicing pathologists regularly employ in their investigations. Presently, several systems are available for morphometrical image analysis, but they require expensive hardware and software attachments. Image J serves as a cost effective alternative which is a freely available java-based public-domain image processing and analysis program developed at the National Institutes of Health

(NIH) (Noguchi *et al.*, 2003), (Ho *et al.*, 2003) (Tchoukalova *et al.*, 2003).

The validity of Image J has been demonstrated in several studies, including the research on oral carcinogenesis (Wu *et al.*, 2003), (Katayama *et al.*, 2004). The studies display the influence of Image J in the outcome of their research. This technique provides the advantage of better reproducibility and accuracy as compared to the conventional counting over the microscope. (Girish and Vijayalakshmi, 2004) Image J delivers a lot despite being a freeware. A study by Natarajan *et al.* (2010) has employed the technique of nuclear morphometry in OSCC to predict the lymph node metastasis. They concluded that morphometric analysis can be effectively used to assess nuclear features preoperatively and enables early detection of cellular changes efficiently (Natarajan *et al.*, 2010). A study was carried out by T Smitha *et al.* (2011) applying morphometric analysis to observe and compare the changes in nuclear and cellular size, shape and nuclear-cytoplasmic ratio of cells, in the basal layer of oral leukoplakia and well-differentiated oral squamous cell carcinoma. The results revealed that the values of nuclear perimeter and area, along with cellular perimeter and area, gradually increased as they moved from the normal buccal mucosa to leukoplakia, reaching the highest value in OSCC (Smitha *et al.*, 2011).

Giardina *et al.* (1996) conducted a study to highlight the significance of nuclear morphometry in squamous cell carcinoma of the tongue. They analysed 30 cases of carcinoma of the tongue to study the relationship between nuclear shape and survival, by dividing the patients into the groups of short term and long term survival. They established that morphometrical analysis could successfully distinguish patients of the two groups with only a 10% error (Giardina *et al.*, 1996). These studies coordinate with the results of morphometrical analysis in our study, conducted using "Image J 1.34 software", with which we could objectively assess the tissue sections of progressive grades of OSCC. The nuclear area, cell area,

nuclear perimeter and cell perimeter were found to show significant alterations in the different grades of OSCC. The analysis was easy and quick and highly reproducible between the two different observers. However, few studies on morphometry have shown faintly dissimilar results. For instance, Shabana *et al.* (1987) studied 100 specimens from oral mucosa to evaluate the size and shape of the cells in the basal cell layer of the oral epithelium, by using an interactive image analysis system (IBAS-1). The results revealed that the size of the nucleus was twice as large in OSCC as in normal mucosa (Shabana *et al.*, 1987).

Morphometry has also been employed to study lesions which may progressively lead to OSCC (Venkatesiah *et al.*, 2013), (Teresa *et al.*, 2007). For instance, Venkatesiah *et al.* (2013) conducted a retrospective study using morphometric image analysis to analyse the nuclear and cellular alterations in oral lichen planus, lichenoid lesions and normal oral mucosa. They worked on Hematoxylin and eosin sections for Cellular and nuclear morphometric measurements using image analysis software. Their results showed that morphometry can differentiate lesions of oral lichen planus and oral lichenoid lesions from normal oral mucosa (Venkatesiah *et al.*, 2013). Thus, morphometry may also be helpful in foretelling the risk of oral malignant transformation.

Conclusion

Several nuclear and cellular changes occur throughout the process of carcinogenesis which hold diagnostic and prognostic relevance. The method of subjective histological examination and grading alone may fall short of correct assessment of OSCC as the tumor shows vast behavioural diversity. However, morphometry can detect the nuclear and cellular changes which can be overlooked by routine histological methods and thus provide an insight into the clinical behaviour of the tumor. It can function as a simple yet promising adjunct which helps in diagnosing and understanding OSCC and can be highly valuable tool in predicting an accurate and timely prognosis in order to formulate an effective treatment plan according to the individual treatment needs of the patient.

REFERENCES

- Abbey LM, Kaugars GE, Gunsolley JC, Burns JC, Page DG. 1995. Intraexaminer and interexaminer reliability in the diagnosis of oral epithelial dysplasia. *Oral. Surg. Oral. Med. Oral Pathol. Radiol. Endod.*, 80:189–91. PMID: 7552884
- Abdel-Salam M(1), Mayall BH, Hansen LS, Chew KL, Greenspan JS. 1987. Nuclear DNA analysis of oral hyperplasia and dysplasia using image cytometry. *Oral Pathol.*, Oct;16(9):431-5.
- Baak JP, ten Kate FJ, Offerhaus GJ, van Lanschot JJ, Meijer GA. 2002. Routine morphometrical analysis can improve reproducibility of dysplasia grade in Barrett's oesophagus surveillance biopsies. *J. Clin. Pathol.*, 55:910–916
- Brothwell DJ, Lewis DW, Bradley G, Leong I, Jordan RC. 2003. Observer agreement in the grading of oral epithelial dysplasia. *Community Dent Oral Epidemiol.*, 31:300–5. PMID: 12846853
- Debora Barreto Teresa, Karina Antunes Neves, Carlos Benatti Neto, Paula Andrea Gabrielli Fregonezi, Maria Rita Brancini de Oliveira, José Antonio Sampaio Zuanon, Eduardo Antonio Donadi, Celso Teixeira Mendes-Junior, Christiane Pienna Soares. 2007. Computer-assisted analysis of cell proliferation markers in oral lesions. *Acta. Histochemica.*, 109(5),377–387.
- Giardina C, Caniglia DM, D'Aprile M, Lettini T, Serio G, Cipriani T, Ricco R, Pesce Delfino V. 1996. Nuclear morphometry in squamous cell carcinoma (SCC) of the tongue. *Eur. J. Cancer B. Oral Oncol.*, Mar; 32B(2):91-6. PMID: 8736170.
- Girish V., A. Vijayalakshmi. Affordable image analysis using NIH Image/Image J. *Indian J. Cancer.*, 41 (2004), p. 47
- Ho CC, Yang XW, Lee TL, Liao PH, Yang SH, Tsai CH, *et al.* 2003. Activation of p53 signalling in acetylsalicylic acid-induced apoptosis in OC2 human oral cancer cells. *Eur. J. Clin. Invest.*, 33:875- 82.
- Karabulut A, Reibel J, Therkildoen MH, Practorius J, Nielsen HW. 1995. Observer variability in the histologic assessment of oral premalignant lesions. *J. Oral Pathol. Med.*, 24:198–200. PMID: 7616457
- Katayama A, Bandoh N, Kishibe K, Takahara M, Ogino T, Nonaka S, *et al.* 2004. Expressions of matrix metalloproteinases in early-stage oral squamous cell carcinoma as predictive indicators for tumor metastases and prognosis. *Clin Cancer Res.*, 10:634-40.
- Khandelwal S, Solomon MC. 2010. Cytomorphological analysis of keratinocytes in oral smears from tobacco users and oral squamous cell carcinoma lesions - A histochemical approach. *Int. J. Oral Sci.*, Mar;2(1):45-52.
- Khoo SP, Primasari A, Saub R. 2001. Nuclear and cellular volumetric alterations in oral lichen planus and lichenoid lesions: a histomorphometric study. *J. Oral Sci.*, Sep; 43(3):151-7.
- Kulasekara KK, Lukandu OM, Neppelberg E, Vintermyr OK, Johannessen AC, Costea. 2009. Cancer progression is associated with increased expression of basement membrane proteins in three-dimensional in vitro models of human oral cancer. *Arch. Oral Biol.*, 2009, Oct; 54(10):924-31. PMID: 19674736.
- Mukherjee S, Katarkar A, Ray JG, Chaudhuri K. 2012. Immunohistochemical markers to differentiate oral precancerous and cancerous lesion: an integrated tissue-based microscopic analysis. In: Méndez-Vilas A, editor. Current microscopy contributions to advances in science and technology: *Formatex Research Center*, pp. 433-438
- Natarajan S, Mahajan S, Boaz K, George T. 2010. Prediction of lymph node metastases by preoperative nuclear morphometry in oral squamous cell carcinoma: a comparative image analysis study. *Indian J. Cancer.*, Oct-Dec; 47(4):406-11. PMID: 21131754
- Noguchi M, Kikuchi H, Ishibashi M, Noda S. 2003. Percentage of the positive area of bone metastasis is an independent predictor of disease death in advanced prostate cancer. *Br. J. Cancer.*, 88: 195-201.
- Patel V, Iglesias-Bartolome R, Siegele B, Marsh CA, Leelahavanichkul K, Molinolo AA, Gutkind JS. 2011. Cellular systems for studying human oral squamous cell carcinomas. *Adv. Exp. Med. Biol.*, 720:27-38. PMID: 21901616

- Pich A., Chiusa L. and Navone R. 2004. Prognostic relevance of cell proliferation in head and neck tumors. *Annals of Oncology*, 15:1319–1329. PMID: 15319236
- Pindborg JJ, Reibel J, Holmstrup P. 1985. Subjectivity in evaluating oral epithelial dysplasia, carcinoma in situ and initial carcinoma. *J. Oral Pathol.*, 14:698–708. PMID: 3932623
- Remmerbach TW, Wottawah F, Dietrich J, Lincoln B, Wittekind C, Guck J. 2009. Oral cancer diagnosis by mechanical phenotyping. *Cancer Res.*, 1;69(5):1728-32.
- Shabana AH, el-Labban NG, Lee KW. 1987. Morphometric analysis of basal cell layer in oral premalignant white lesions and squamous cell carcinoma. *J. Clin. Pathol.*, Apr;40(4):454-8. PMID: 3584491.
- Smitha T., P. Sharada, and HC Girish. 2011. Morphometry of the basal cell layer of oral leukoplakia and oral squamous cell carcinoma using computer-aided image analysis *J. Oral Maxillofac Pathol.*, Jan-Apr; 15(1): 26–33. PMID: 21731274.
- Tchoukalova YD, Harteneck DA, Karwoski RA, Tarara J, Jensen MD. 2003. A quick, reliable, and automated method for fat cell sizing. *J. Lipid Res.*, 44:1795-801.
- Venkatesiah SS, Kale AD, Hallikeremath SR, Kotrashetti VS. 2013. Histomorphometric analysis of nuclear and cellular volumetric alterations in oral lichen planus, lichenoid lesions and normal oral mucosa using image analysis software. *Indian J. Dent Res.*, Mar-Apr; 24(2):277. PMID: 23965463
- Wu KH, Madigan MC, Billson FA, Penfold PL. 2003. Differential expression of GFAP in early v late AMD: a quantitative analysis. *Br. J. Ophthalmol.*, 87:1159-66.
