



ISSN: 0975-833X

## RESEARCH ARTICLE

### AN ANOMALOUS COMMUNICATION BRANCH - KUGEL'S ARTERY

<sup>1</sup>Vasudeva Reddy, J. and <sup>2</sup>Lokanadham, S.

<sup>1</sup>Department of Anatomy, Sri Venkateswara Medical College, Tirupati, Andhrapradesh

<sup>2</sup>Department of Anatomy, ViswaBharathi Medical College, Kurnool, Andhrapradesh

#### ARTICLE INFO

##### Article History:

Received 26<sup>th</sup> December, 2012

Received in revised form

04<sup>th</sup> January, 2013

Accepted 21<sup>th</sup> February, 2013

Published online 19<sup>th</sup> March, 2013

##### Key words:

Arteria anastomotica auricularis magna,  
Communication, Circumflex artery.

#### ABSTRACT

The course of the coronary vasculature and their communication branches plays an important role in clinical cardiac angiography. A small vessel running through the atrial septum which links the anterior coronary arteries to the posterior ventricular coronary tree is termed as Kugel's artery. The present study we observed an anomalous branch originating from the left circumflex artery and communicating with right coronary artery, which intend termed as Kugel's artery. The incidence of this branch in south Indian population is about 3.75% in our study was observed along with anastomosis between the anterior and posterior descending arteries. Most of the literatures stating that the anastomosis between coronary arteries are having significant role in clinical diagnostics. Our study acknowledges the kugel's artery and its importance in angiographic studies to help the clinicians and surgeons.

Copyright, IJCR, 2013, Academic Journals. All rights reserved.

#### INTRODUCTION

Kugel's artery (arteria anastomotica auricularis magna) is a small communication branch between the left circumflex and right coronary artery (Williams, *et al.*, 2000 and James 1961) According to KUGEL the artery presents three anatomic variations; in majority of the cases it originates from the left circumflex artery, penetrates the left atrial wall and proceeds backward through the inferior border of the atrial septum to the crux (James, 1961 and Kugel, 1927). Occasionally Kugel's artery originates from the sinus nodal artery. In the second variation, kugel's artery formed by a branch of the right coronary artery and a branch of the left circumflex artery which join near the atrioventricular node artery. In the third variation, the artery originates from the left circumflex artery and splits into smaller branches, which connect to similar small coming from the right coronary artery at the crux level (Kugel, 1927). The artery is not as large as stated by Kugel it should be demonstrated by arteriogram in addition to coronary angiography.

#### MATERIALS AND METHODS

A total (n=80) heart specimens were collected with a portion of ascending aorta from relatively fresh bodies that came for post-mortem at the Forensic Department, S.V. Medical College, Tirupati. Each specimen thoroughly washed to free it from the blood clots and dissected. The arterial pattern of heart from the origin of the coronary arteries to their termination observed and variations are recorded. Radio opaque medium (BaSO<sub>4</sub>) was injected into each coronary artery. Both coronary arteries were injected simultaneously depending on the size of the heart, in order to render the arteries and their branches clearly visible to the naked eye. We took care to avoid occlusion of the atrial branches originating from the beginning of the coronary arteries. In addition, radiographic films were made in anteroposterior, posteroanterior, lateral, and left and right anterior oblique projections. The arteriogram for all specimens collected from the Cardiology Department.

\*Corresponding author: loka.anatomy@yahoo.com

#### RESULTS

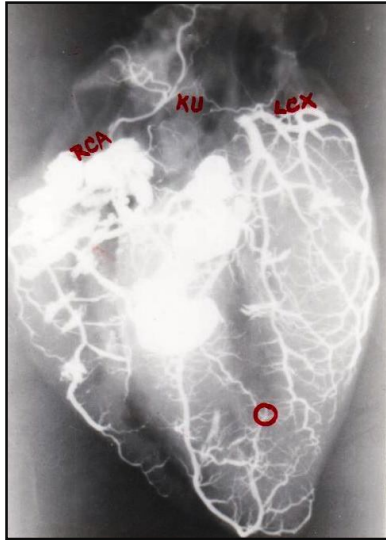
##### Case Study

In the present study we collected 80 heart specimens from forensic medicine department and dissected as well as prepared the specimens for arteriogram. We studied the arterial pattern of coronary arteries from their origin to termination was observed. We also studied the circulation pattern of the coronary arteries and their abnormalities were noticed. We found an anomalous communication between the right coronary artery and left circumflex artery. In the same case we found the anastomosis between the anterior descending and posterior descending arteries (Figure 1). The arteriogram are visualised clearly and labelled from the cardiology department. This study is under clearance with Human ethical committee, S.V. Medical College, Tirupathi.

#### DISCUSSION

Kugel's artery an atrial artery that connected directly or through the sinus node artery the proximal part of the Left circumflex artery or the Right coronary artery with the distal part of the vessel where it crossed the crux (James 1961). This artery is long and wide, and suitably fulfils the 4 initial descriptive term "arteria anastomotica auricularis magna" given by Kugel (Kugel, 1927). Out of 80 heart specimens we observed the communication channel between left circumflex artery and right coronary artery with incidence of 3.75%. We have not studied about morphometry of the coronary arteries. In our study the kugel's artery is arising from the left circumflex in origin and communicating with right coronary artery. The branch is smaller so it is too difficult to study about its morphometry hence observed through angiographic arteriogram. Similar Percentages ranging between 3.6% and 6%, albeit in patients with severe atherosclerotic heart disease, have been reported in the literature, in 3 coronary angiographic studies (Grollman, Heger 1978; Levin 1974, and Soto, Jochem, Karp 1973). Our study findings and incidence are mere with above study. The incidence of kugel's artery in anatomical studies is very high 40% to 66% is due to the more number of cases with high incidence of

communicating network (Kugel 1927 and Smith, Amplatz, 1973). The sinus node artery or its branches contributed to the formation of this network, an observation that has been mentioned by others (Kennel, and Titus, 1972; Nerantzis *et al.*, 1983). In one study, the participation of Kugel's artery was found to be as high as 40% (Abuin and Nieponice, 1998). It is difficult to demonstrate Kugel's artery in post-mortem angiography (James, 1970). Kugel reported that in some cases his artery connected directly with the distal right coronary artery, while in all other cases it connected via the Atrioventricular nodal artery (Kugel, 1927).



#### Legends

Figure 1. Arteriogram showing Kugel's Artery is visualised which is a communicating channel between right coronary and left circumflex artery (RCA: right coronary artery, KU: Kugel's artery unusual branch; LCX: left circumflex). The anastomosis (O) is observed between anterior (LAD) and posterior descending (PD) arteries.

#### Conclusion

Kugel stated that Kugel's artery originates from the left circumflex artery, penetrates the left atrial wall and proceeds backward through the inferior border of the atrial septum to the crux (James, 1961). In our study the findings and course of the Kugel's artery is originating from the left circumflex and communicating with right coronary artery.

The artery is not as large as stated by Kugel it should be demonstrated by arteriogram in addition to coronary angiography (James, 1970). Prompt knowledge of communicating branches from the coronary vessels is very essential to the clinicians and surgeons with high significance.

#### Acknowledgement

Authors are thankful to Dr. R. V. Subhakar, Professor, for his able guidance and special thanks to Dr. R. Sekhar, Professor, for his constant encouragement for this work.

#### REFERENCES

- Abuin G, Nieponice A. New findings on the origin of the blood supply to the atrioventricular node. Clinical and surgical significance. *Tex Heart Inst J* 1998; 25:113-7.
- Grollman JH Jr, Heger L. Angiographic anatomy of the left Kugel's artery. *Cathet Cardiovasc Diagn* 1978;4:127-33.
- James T.N; Anatomy of the coronary arteries. Paul B Hoeber.Inc. New York.1961; 12-150.
- James TN. The delivery and distribution of coronary collateral circulation. *Chest* 1970; 58:183-203.
- Kennel AJ, Titus JL. The vasculature of the human sinus node. *Mayo Clin Proc* 1972; 47:556-61.
- Kugel MA. Anatomical studies on the coronary arteries and their branches. I. Arteria anastomotica auricularis magna. *Am Heart J* 1927; 3:260-70.
- Levin DC. Pathways and functional significance of the coronary collateral circulation. *Circulation* 1974;50:831-7.
- Nerantzis CE, Toutouzas P, Avgoustakis D. The importance of the sinus node artery in the blood supply of the atrial myocardium. An anatomical study of 360 cases. *Acta Cardiol*1983; 38:35-47.
- Smith C, Amplatz K. Angiographic demonstration of Kugel's artery (arteria anastomotica auricularis magna). *Radiology* 1973;106:113-8
- Soto B, Jochem W, Karp RB, Barcia A. Angiographic anatomy of the Kugel's artery. *Am J Roengenol Radium Ther Nucl Med* 1973;119:503-7.
- Williams PL, Bannister LK, Berry MM, Collins P, Dyson M, Dussek JE, Ferguson MWJ; Grays Anatomy. 38th Ed. Edinburgh, Churchill Livingstone; 2000; 1505-1510.

\*\*\*\*\*